

Blood Parasite Identification

Thick and thin Giemsa-stained smears were obtained from a 42-year-old female who recently visited family in Liberia. A response of "No parasite(s) seen" or "Specimen screened for blood parasites, no organisms seen" was considered satisfactory.

BP-06	Parasite Identification	Referees (31)	Participants (412)		
		No.	%	No.	%
	No parasite(s) seen	31	100.0	397	96.4
BP-06	Parasite Screen	Referees (19)	Participants (814)		
		No.	%	No.	%
	Specimen screened for blood parasites, no organisms seen	19	100.0	782	96.1

Discussion

Identification

Careful examination of multiple thin and thick blood films is imperative to exclude the diagnosis of blood parasites, particularly for patients living in endemic areas. For thin films: (1) all blood components (erythrocytes, white blood cells, and platelets) should be intact, (2) the background should be clean and free from debris, (3) erythrocytes should stain a pale grayish-pink, and neutrophilic leukocytes should have deep purple nuclei and well defined granules, and (4) erythrocytes at the terminal, feathered end of the film should be adjacent, but not overlap (one layer thick). For thick films: (1) the background should be clean, free from debris, with a pale mottled-gray color derived from lysed erythrocytes, (2) leukocytes should stain deep purple with pale purple cytoplasm, and (3) eosinophilic granules should stain a bright purple-red and neutrophilic granules should stain deep pink-purple.

Thick films are most useful for screening since they provide a larger quantity of blood for examination. Thin films, on the other hand, are most useful for speciation since they provide the best red blood cell (RBC) and parasite morphology. All requests for peripheral blood smear examination to detect *Plasmodium* spp. should be performed without delay. Both thick and thin films should first be fully screened at low power (ie, using the 10x objective) to detect microfilaria which may be present in low numbers anywhere on the slides and which may not be detected in the standard 300 field slide review at higher magnification.

Due to the severe implications of a misdiagnosis, laboratory personnel should then examine at least 300 oil immersion fields (using the 100X oil immersion objective) for each thick and thin blood film. In addition, one set of blood films is not sufficient to exclude the diagnosis of malaria and the laboratory should recommend collection of multiple blood specimens approximately at 6-8 hour intervals to definitively exclude the presence of blood parasitemia. This comment should accompany the final report "No blood parasites seen."

References

1. Garcia LS. 2007. *Diagnostic Medical Parasitology*, 5th ed., Washington, DC. ASM Press.
2. CDC: Malaria surveillance - United States 2008. *MMWR* 2010;59(SS07);1-15.
3. Greenwood BM, Bojang K, Whitty CJ, Targett GA. Malaria. *Lancet*. 2005;365:1487-1498.

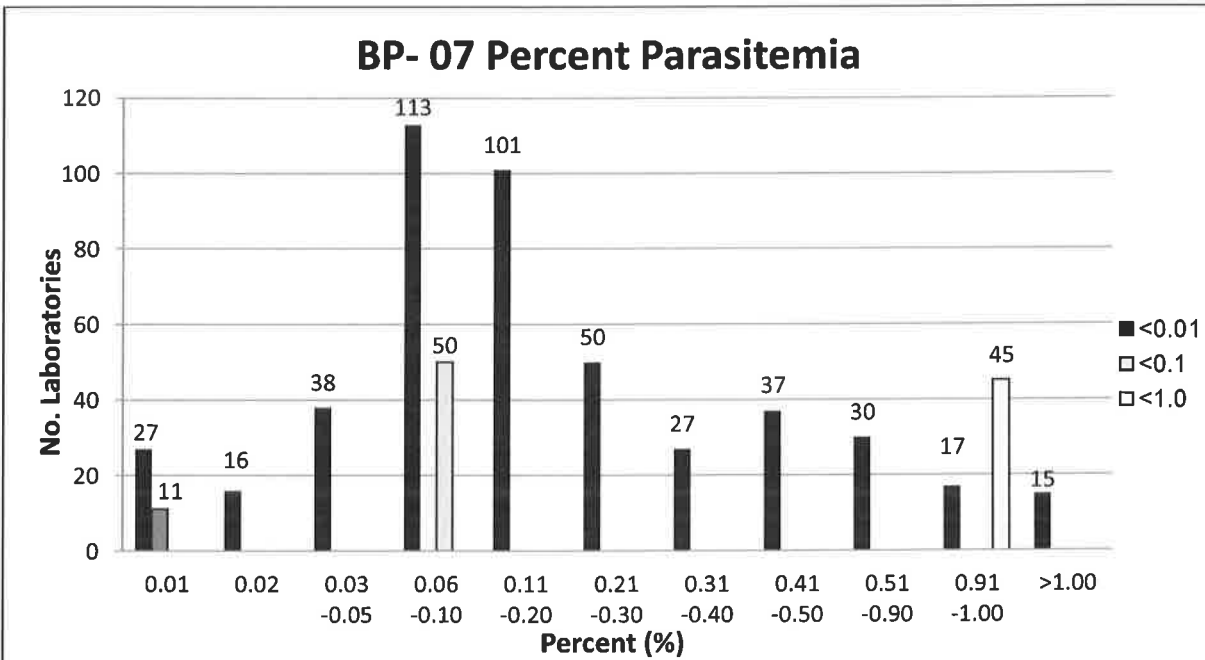
BP-07 Introduction

Thick and thin Giemsa-stained smears were obtained from a 36-year-old male returning from visiting family in Kenya. The specimen contained *Plasmodium falciparum*. A response of "*Plasmodium falciparum*", "*Plasmodium* sp., NOS would refer or request another specimen, or perform additional molecular testing" and "*Plasmodium* sp./*Babesia* sp. seen, referred for identification" were considered satisfactory.

BP-07	Parasite Identification		Referees (34)		Participants (456)	
			No.	%	No.	%
	<i>Plasmodium falciparum</i>		33	97.1	392	86.0
	<i>Plasmodium</i> sp., NOS would refer or request another specimen, or perform additional molecular testing		-	-	49	10.8
BP-07	Parasite Screen		Referees (19)		Participants (788)	
			No.	%	No.	%
	<i>Plasmodium</i> sp./ <i>Babesia</i> sp. seen, referred for identification		18	94.7	757	96.1
	Specimen screened for blood parasites, no organisms seen		1	5.3	29	3.7

BP-07

If you have identified a *Plasmodium* sp. or *Babesia* sp.: Report percent of infected RBCs seen (number of infected RBCs per 100 red blood cells). (Ungraded)



Key morphologic features on thin blood film that suggests a diagnosis of *P. falciparum* may include:

- Normal size and shape of infected erythrocytes
- Smaller, more delicate ring stages (approximately 1/5 the diameter of the erythrocyte) frequently with two chromatin dots (so-called "head phone" forms)
- Erythrocytes infected with multiple ring forms
- Presence of ring forms at the edge of the erythrocyte (appliqué forms)
- Absence of mature trophozoites and schizonts in the peripheral blood film (may be seen if there is a delay in processing the blood specimen)
- Presence of crescent-shaped gametocytes (not always seen)
- Absence of Schüffner's stippling. Larger, comma-shaped dots (Maurer's clefts) may be seen, especially when the stain buffer is at a pH of 7.2

Distinguishing *P. falciparum* from *Babesia* spp. can be challenging, given that both have a predominance of small ring forms, infect RBCs of all ages, and can produce multiply infected red blood cells (RBCs). The presence of Maurer's clefts, malarial pigment, and banana-shaped gametocytes eliminate *Babesia* infection from consideration. Furthermore, *Babesia* parasites are usually more pleomorphic with spindled, elliptical and ovoid forms. Extracellular forms are also more common in babesiosis. Finally, identification of the classic "Maltese cross" or tetrad form of *Babesia* sp. is diagnostic for babesiosis. Molecular or antigen-detection methods, in addition to clinical/travel history may be useful adjuncts for distinguishing between these two similar appearing parasites.

Discussion

Causal Agents:

There are four species of *Plasmodium* that cause human malaria: *P. falciparum*, *P. malariae*, *P. ovale*, and *P. vivax*. In addition, there are at least six species of simian *Plasmodium* that have been documented to cause zoonotic infections in humans, the most notable being *P. knowlesi*, infections of which appear to be increasing on the Malaysian peninsula.

Plasmodium falciparum occurs nearly worldwide in the tropics and subtropics, particularly in Africa and Southeast Asia. *Plasmodium malariae* also occurs nearly worldwide in the tropics and subtropics, but has a more patchy distribution than *P. falciparum*; most common in tropical Africa, Indian subcontinent, and Southeast Asia. *Plasmodium ovale* occurs primarily in tropical western Africa, but also New Guinea and Southeast Asia; *P. ovale* has not yet been documented from the New World. *Plasmodium vivax* occurs nearly worldwide in the tropics, subtropics, and some regions of northern and eastern Africa, the Middle East, the Indian subcontinent, Southeast Asia, and the Americas.

Biology and Life Cycle:

Plasmodium spp. are transmitted by mosquitoes in the genus *Anopheles*. Infected female mosquitoes inject sporozoites when taking a blood meal. Sporozoites are carried via blood to the liver where they invade hepatocytes and form schizonts. The liver schizonts rupture, releasing large numbers of merozoites that then invade erythrocytes starting the erythrocytic cycle. Early ring forms develop into mature trophozoites and take one of two pathways: 1) they develop into schizonts (which rupture and continue the erythrocytic cycle) or 2) develop into gametocytes. Gametocytes are a dead-end stage in the human host but are required for sexual reproduction in the mosquito. In the mosquito host, microgametocytes (=males) exflagellate and fertilize macrogametocytes (=females), resulting in an ookinete. Ookinetes further develop into oocysts, which when mature rupture and release the infective sporozoites. In *P. falciparum*, late trophozoites and schizonts express a protein on the surface of the erythrocytic membrane causing the infected erythrocyte to adhere to the endothelial lining of capillaries in internal organs. Thus, only ring forms and gametocytes are usually seen in well-prepared peripheral blood smears.

Diagnosis:

The ideal specimen for laboratory identification of malaria is fresh capillary blood from a finger or heel stick, with immediate preparation of thick and thin blood films. Since this is not feasible in most settings, however, venous blood collected in EDTA anticoagulant is also acceptable. It is important to transport the blood as quickly as possible to the laboratory for examination since prolonged exposure to EDTA may result in distortion of the malaria parasites and compromised morphology.

Malaria is primarily diagnosed by the identification of *Plasmodium* parasites on thin and thick blood films stained with Giemsa, Wright, or Wright-Giemsa stain. Molecular methods such as PCR may be employed when an identification cannot be made morphologically or there is morphologic evidence of a mixed infection. Rapid diagnostic tests are also commonly used to distinguish *P. falciparum* from other malaria infections. Serology is not used for routine diagnosis but may be helpful during transfusion investigations.

Typically, thick films are used for the recognition of *Plasmodium*, with a species-level identification performed on the thin film. Thin films should be read at 1000x magnification with oil for at least 100 microscopic fields. Immunologically naïve patients (eg, returning travelers born in non-endemic areas) may present with stronger clinical manifestations at a lower parasitemia. Severe malaria is currently defined as a parasitemia $\geq 2\%$ in immunologically naïve patients and $\geq 5\%$ in non-naïve patients.

Morphologic Identification:

Two important questions regarding morphologic identification of malaria are:

- 1) Is it malaria?
- 2) Is it *Plasmodium falciparum*?

Recognition of *Plasmodium* is based on observing stages of the parasite inside infected red blood cells. In a well-prepared specimen, the cytoplasm will stain blue and the chromatin red. Pigment (which is absent in *Babesia* infections) will present as golden-brown to black flecks. In some species, structures such as Schüffner's stippling or Maurer's clefts may be present when stained at an appropriate pH. Identification of *Plasmodium* to the species level is extremely important for patient management, as different species may be treated differently (for example, it is important to target the liver stages of *P. ovale* and *P. vivax* to prevent relapse of the disease).

The following table compares the morphologic features of the four stages of human *Plasmodium* spp.

Morphologic Criteria	<i>Plasmodium falciparum</i>	<i>Plasmodium malariae</i>	<i>Plasmodium ovale</i>	<i>Plasmodium vivax</i>
Size of infected RBC	Normal	Normal to smaller	Enlarged	Enlarged
Rings (early trophozoites)	Common; usually with thin, delicate cytoplasm and double chromatin dots; often multiple rings per infected RBC; appliqué forms common	Cytoplasm sturdy, usually with single, large chromatin dot; occasional 'birds-eye' forms	Cytoplasm sturdy, with 1-2 large chromatin dots	Large, sturdy cytoplasm, usually with large, single chromatin dot
Developing trophozoites	Rare, but may be seen if a delay in processing; form compact, pigment usually evident	Variable; may be compact to elongate (band-form) or pleomorphic and vacuolated (basket-form); pigment coarse	Compact to slightly amoeboid with dark pigment; elongation and fimbriation may be observed	Pleomorphic to grossly amoeboid; pigment diffuse and golden-brown to nearly black
Schizonts	Rare in peripheral blood; 8-24 small merozoites when mature; pigment dark, compact	6-12 merozoites when mature, often in a rosette pattern around central mass of pigment	6-14 merozoites when mature; pigment dark brown to black and discrete when mature; elongation and fimbriation may be present	12-24 merozoites when mature; may fill entire RBC; often noticeable enlarged
Gametocytes	Crescent-shaped; chromatin discrete (macrogametocyte) or diffuse (microgametocyte); Laveran's bib may be present	Small, round, compact; pigment coarse and diffuse	Round to oval, compact; if elongated and fimbriated may not fill entire infected RBC; pigment coarse, dark	Large and round to pleomorphic (may 'hug' surrounding RBCs); may fill most of infected RBC; pigment golden-brown to nearly black
Other Features	Maurer's clefts may be present; ring-form trophozoites usually predominate	Generally smaller; pigment coarse; Ziemann's stippling may be present; all stages seen	Schüffner's stippling may be present at appropriate pH; elongation and fimbriation may be observed; all stages seen	Schüffner's stippling may be present at appropriate pH; enlargement of infected RBCs usually pronounced; all stages seen

Calculating Percent Parasitemia:

The percent parasitemia is very important to calculate for prognostic purposes and also to evaluate response to antimalarial therapy.

Parasitemia can be calculated on a thin blood film as follows:

1. Count the number of infected RBCs per 100 RBCs in different oil immersion fields.
2. Apply the formula:

$$\frac{\text{\# of infected RBCs}}{\text{total \# of RBCs counted}} \times 100 = \% \text{ parasitemia}$$

Notes:

- 1) At least 500 RBC's should be counted, with counting 2000 or more RBCs providing the most accurate estimation of parasitemia
- 2) An infected RBC containing multiple parasites is calculated only once
- 3) Fields devoid of parasites should be included, if encountered
- 4) Gametocytes should not be included in the count. Justification is because: a) many antimalarial drugs are not gametocidal and the presence of gametocytes post-treatment is not indicative of the effectiveness of the treatment and b) gametocytes are a dead-end stage in the human host.

Clinical Significance:

In 2014, ninety seven countries and territories had ongoing malaria transmission. Over half a million people die from malaria each year. Most malaria cases and deaths occur in children in sub-Saharan Africa. In 2011, a 40-year high of 1,925 cases of malaria were reported to the CDC in the United States, almost all in recent travelers and immigrants. Although the *Anopheles* mosquito is endemic in parts of North America, malaria transmission was largely eradicated in the 1940s through public health efforts.

Malaria infection can be classified as either uncomplicated or severe (complicated). In uncomplicated infections, patients present with nonspecific symptoms including fever, chills, sweats, headaches, nausea/vomiting, body aches and malaise. Symptoms classically (but infrequently observed) recur either in a two-day cycle (*P. falciparum*, *P. vivax* and *P. ovale*) or in three-day cycle (*P. malariae*). In severe infections, organ failure and/or metabolic abnormalities occur including severe anemia, acute respiratory distress syndrome, acute kidney failure, metabolic acidosis, cerebral infection, and coagulation abnormalities. Severe infection is considered a medical emergency requiring urgent treatment. *Plasmodium falciparum* can cause severe illness and death whereas *P. vivax*, *P. malariae* and *P. ovale* tend to cause less severe illness. The hypnozoite form of *P. vivax* and *P. ovale* can remain dormant in a patient's liver and cause relapsing infection.

Treatment:

Treatment of malaria should ideally wait until a laboratory diagnosis has been made. Treating "presumptively" should occur only when no other option exists. Therapy is guided by the infecting species of *Plasmodium*, the clinical status of the patient and the drug susceptibility of the infecting parasites (dependent on geographic area and previous anti-malarial treatment). Because of the rapid progression of *P. falciparum* infections and a high risk of fatality, urgent treatment is essential.

If the infection is uncomplicated, oral anti-malarial medication can provide effective treatment. However, severe infections necessitate parenteral therapy. *Plasmodium falciparum* and *P. vivax* have different drug resistance patterns in different geographic regions. Although not readily available in North America, the WHO recommends artemisinin-based combination therapy as first-line treatment in uncomplicated *P. falciparum* malaria (oral administration), severe malarial infections (intravenous administration) and *P. vivax* infections in areas of known chloroquine resistance. Other, non-artemisinin based combination treatments include sulfadoxine-pyrimethamine

plus either chloroquine, amodiaquine, or atovaquone-proguanil. In recent years, resistance to artemisinin has been detected in Cambodia, Laos, Myanmar, Thailand and Vietnam. For confirmed *P. vivax* and *P. ovale* infections, radical cure can be achieved with treatment using primaquine and in order to prevent relapse due to the hypnozoite form. In high-transmission settings re-infection with *P. vivax* is likely. Mixed-species malarial infections are not common but may be underestimated by routine microscopy.

References

1. Centers for Disease Control and Prevention. Treatment of Malaria: Guideline for Clinicians. Available at: http://www.cdc.gov/malaria/diagnosis_treatment/clinicians3.html. Accessed June 23, 2015.
2. World Health Organization. Guidelines for the Treatment of Malaria. 3rd ed. Geneva, 2015.
3. World Health Organization. Malaria: Fact Sheet #94. Updated December 2014. Available at: <http://www.who.int/mediacentre/factsheets/fs094/en/> Accessed online October 26, 2015.
4. Garcia LS. *Diagnostic Medical Parasitology*. 5th ed. Washington, DC. ASM Press; 2007.
5. CDC: Malaria surveillance – United States 2005. *MMWR* 2007;56(SS06);23-38.
6. Greenwood BM, Bojang K, Whitty CJ, Targett GA. Malaria. *Lancet*.2005;365:1487-1498

BP-08 Introduction

Thick and thin Giemsa-stained smears were obtained from a symptomatic refugee from the Democratic Republic of Congo undergoing routine screening. A response of "No parasite(s) seen" or "Specimen screened for blood parasites, no organisms seen" was considered satisfactory.

BP-08	Parasite Identification	Referees (31)		Participants (411)	
		No.	%	No.	%
	No parasite(s) seen	31	100.0	397	96.6
BP-08	Parasite Screen	Referees (19)		Participants (812)	
		No.	%	No.	%
	Specimen screened for blood parasites, no organisms seen	19	100.0	768	94.6

Discussion

See BP-06 page 2 for discussion.

BP-09 Introduction

Thick and thin Giemsa-stained smears were obtained from a 26-year-old male presenting with fevers after recently hiking the Appalachian trail. The specimen contained *Babesia* sp. A response of "Babesia sp." and "Plasmodium sp./Babesia sp. seen, referred for identification" were considered satisfactory.

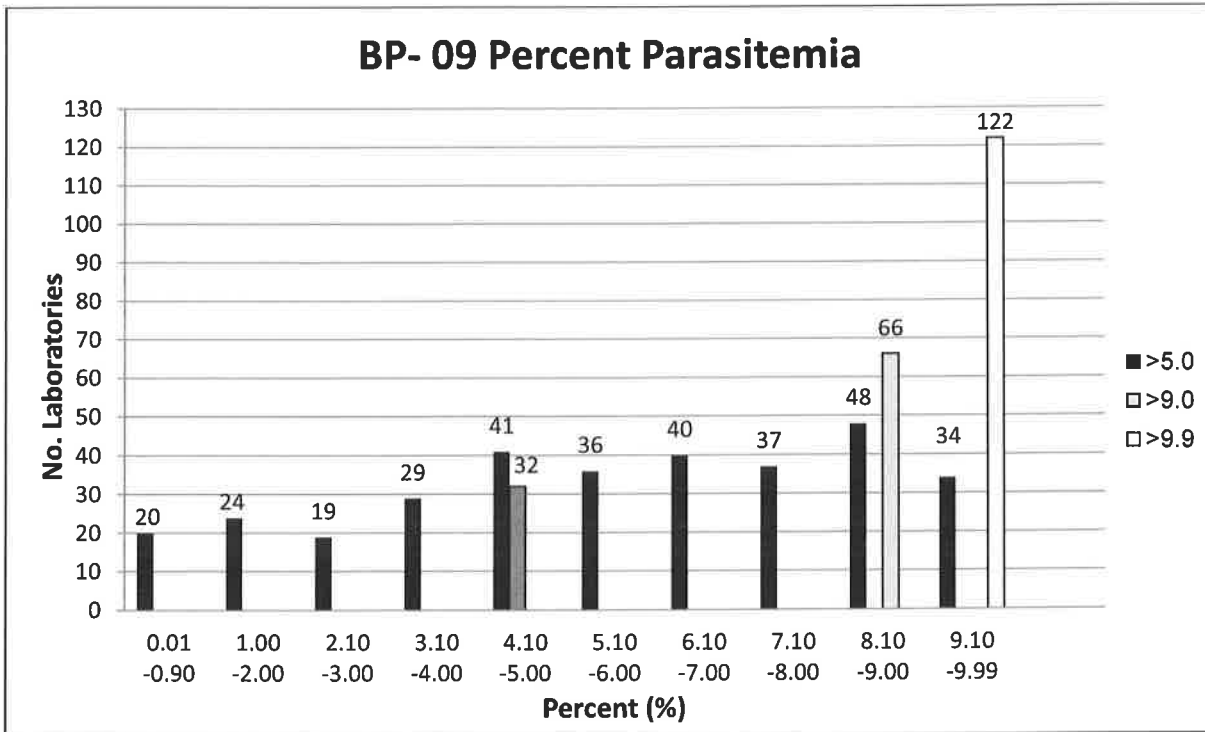
Parasite Identification	Referees (34)		Participants (443)	
	No.	%	No.	%
<i>Babesia</i> sp.	33	97.1	428	96.6
<i>Plasmodium falciparum</i>	1	2.9	9	2.0

Parasite Screen	Referees (19)		Participants (797)	
	No.	%	No.	%
<i>Plasmodium</i> sp./ <i>Babesia</i> sp. seen, referred for identification	19	100.0	780	97.9

BP-09

BP-09

If you have identified a *Plasmodium* sp. or *Babesia* sp.: Report percent of infected RBCs seen (number of infected RBCs per 100 red blood cells). (Ungraded)



Summary of Key Features for Identification:

1. *Babesia* spp. infect red blood cells of all sizes.
2. Only the ring stages are identified on blood smears.
3. Differentiating *Babesia* spp. from *P. falciparum* is sometimes difficult. The distinguishing features of *Babesia* spp. include pleomorphic ring forms, the "Maltese cross pattern" and extracellular forms.

Upon initial presentation of the patient, the parasite may present in such low numbers in blood that they cannot be seen in thin films. The diagnosis then depends on finding parasites in the thick films. If only ring forms are present on the thick films, it may be impossible to distinguish between *P. falciparum* and *Babesia* species. The clinical history along with collection of multiple blood samples then are of extreme importance. Molecular methods (PCR) testing or malarial antigen testing may also be useful in these cases. Confirmed and suspected cases should be reported to the department of health.

Discussion

Causal Agents

Babesiosis is caused by apicomplexan parasites of the genus *Babesia*. Species most-commonly attributed to human disease include *B. microti* (endemic to northeastern and northern midwestern United States; introduced elsewhere), *B. duncani* (northwestern North America), *B. divergens* (Old World), and *Babesia* sp. MO-1 (midwestern United States).

Biology and Life Cycle

Babesia spp. have a two-host life cycle. The definitive hosts are ticks in the genus *Ixodes*, while the intermediate hosts are mammals (usually rodents in nature). Infective sporozoites are released into the mammalian hosts when an infected *Ixodes* takes a blood meal. Sporozoites enter erythrocytes and undergo asexual reproduction by budding. Early ring-form trophozoites give rise to merozoites (including the classic 'tetrad form') that either produce more trophozoites or gametes. The latter is a dead-end stage in the mammalian host, and gametes must be ingested by a tick in order for sexual reproduction to occur. Humans can become infected either by being fed upon by an infected tick or through blood transfusions. Rare congenital cases have also been reported.

Diagnosis

Human babesiosis is typically diagnosed initially by the finding of trophozoites and merozoites on stained blood films. Merozoites displayed in a 'Maltese-cross' formation (tetrads) are typically diagnostic for *Babesia* spp. Trophozoites may be ring-shaped, pyriform (pear-shaped), or pleomorphic and vacuolated, and arranged singly or in short chains. Multiply-infected RBCs are not uncommon. Ring-form trophozoites need to be distinguished from *Plasmodium* spp., especially *P. falciparum*. *Plasmodium* spp. produce pigment, which is never produced by *Babesia* spp. In cases of babesiosis, extracellular ring-forms may be observed, singly or in clusters.

Species-level identification of *Babesia* cannot be reliably accomplished by microscopy alone. Patient travel history can be useful information for determining the species of *Babesia* present, but confirmatory diagnosis should be performed by molecular (PCR, or PCR in combination with sequencing analysis) or serologic methods. Serology can also play a very important role in screening potential donors in transfusion-acquired cases.

Clinical significance

The clinical outcome can vary from asymptomatic infection to death depending on infective organism, presence of other tick-borne infections such as borreliosis, age, host immune status, and other underlying factors (eg, splenectomy or a history of blood transfusions). Presenting symptoms include malaise, chills, myalgia, fatigue, anemia, and high-grade fever not unlike acute malaria. More chronic symptoms described in cases are nausea, vomiting, night sweats, loss of weight, and bloody or dark urine.

Treatment

The majority of babesiosis cases self-resolve without need for drug therapy. The standard of care for more severe cases is clindamycin combined with quinine. An alternative regimen is atovaquone combined with azithromycin. In severe disease, or in splenectomized patients, exchange transfusion may be needed in addition to antimicrobial therapy.

References

1. Ash LP, Orihel TC. *Atlas of Human Parasitology*, 5th ed. Chicago, IL: ASCP Press: 2007.
2. Centers for Disease Control and Prevention, Division of Parasitic Diseases (DPD). *Laboratory Identification of Parasites of Public Concern*. <http://www.cdc.gov/dpdx>
3. Mandell GL, Bennett JE, Dolin R. *Mandell, Douglas, and Bennett's Principles and Practice of Infectious Diseases*, 7th ed. Philadelphia, PA: Churchill Livingstone Elsevier, 2009

BP-10 Introduction

Thick and thin Giemsa-stained smears were obtained from a 45-year-old female with travel to west-central Africa presents with fever, lymphadenopathy, and pruritus. The specimen contained *Trypanosoma brucei*. A response of "*Trypanosoma brucei (gambiense or rhodesiense)*", "Blood flagellate, NOS, referred for identification" and "Blood or tissue parasite, not *Plasmodium* sp. or *Babesia* sp., referred for identification" was considered satisfactory.

BP-10	Parasite Identification	Referees No.	(32) %	Participants No.	(404) %
		<i>Trypanosoma brucei (gambiense or rhodesiense)</i>	31	96.9	394
	<i>Trypanosoma cruzi</i>	1	3.1	12	3.0
BP-10	Parasite Screen	Referees No.	(19) %	Participants No.	(800) %
	Blood flagellate, NOS, referred for identification	16	84.2	688	86.0
	Blood or tissue parasite, not <i>Plasmodium</i> sp. or <i>Babesia</i> sp., referred for identification	2	10.5	101	12.6
	Microfilaria, NOS, referred for identification	1	5.3	10	1.3

Discussion

Causal Agents

African trypanosomiasis is caused by two subspecies of *Trypanosoma brucei*, *T. b. gambiense* (West and Central Africa) and *T. b. rhodesiense* (eastern and southeastern Africa). The type subspecies, *T. b. brucei*, does not cause human infection.

Biology and Life Cycle

Trypanosoma brucei spp. are transmitted by tsetse flies in the genus *Glossina*. When an infected tsetse fly takes a blood meal, metacyclic trypomastigotes are injected into the bloodstream where they transform into bloodstream trypomastigotes. There are two forms of bloodstream trypomastigotes, slender and stumpy. The slender trypomastigotes multiply by binary fission and perpetuate the blood cycle. Stumpy forms are adapted to be picked up by the tsetse fly vector. Within the midgut of the vector, stumpy forms develop into procyclic forms and multiply by binary fission. After a while, some procyclic forms leave the midgut and migrate via the hemocoel to the salivary glands, where they develop into epimastigote and eventually metacyclic forms. Metacyclic forms are non-dividing and are the infectious stage for the vertebrate host. Unlike with *T. cruzi*, there is no amastigote formation in the human host tissue, although *T. brucei* can cross the blood-brain barrier and cause central nervous system involvement.

Diagnosis

Diagnosis of *T. brucei* is made by the finding of trypomastigotes in blood, chancre fluid, lymph node aspirates, bone marrow, and CSF. A wet preparation may be examined for motility. Concentration techniques may increase the chances for a morphologic diagnosis, including centrifugation and examination of the buffy coat.

Trypomastigotes (the only stage seen in the human host) are 14-33 μm long, have a large central nucleus, a small, terminal kinetoplast at the posterior end and a free flagellum leaving the body anteriorly. In stained blood films, it is possible to find dividing forms, something not seen in cases with *T. cruzi*. Currently, serologic, molecular, and rapid diagnostic (RDT) tests are not routinely available in the United States.

Clinical Significance

According to the World Health Organization in 2014, 3796 cases were reported with fewer than 15,000 estimated cases of HAT. Human infection with *Trypanosoma brucei* presents with two clinical manifestations. In the first, the parasite is found in the peripheral blood and symptoms include fevers, headaches, malaise, and muscle and joint aches. In the second, parasites cross the blood-brain barrier to involve the central nervous system and can be found in the cerebrospinal fluid. During second stage disease, neurologic symptoms develop and mental status declines, eventually leading to coma and death. Disease progresses at different rates depending on which subspecies is involved, with *T. b. gambiense* having a more chronic, indolent course spanning years while *T. b. rhodesiense* progresses more rapidly over a period months. If left untreated, both forms of African trypanosomiasis are fatal.

Treatment

All people with trypanosomal infection should be treated. First-line therapy depends on stage of disease and subspecies involved. For *T. b. gambiense* infections, pentamidine isethionate is the drug of choice for first-stage disease while combination therapy with nifurtimox and eflornithine is recommended for second-stage disease. For *T. b. rhodesiense* infections, suramin is the first-line treatment for first-stage disease while melarsoprol is recommended for second-stage disease. These therapies are generally effective yet have varying toxicity profiles. Of note, adverse reactions to melarsoprol can be severe and life-threatening with 5-18% of patients developing an encephalopathic reaction which is fatal in 10-70% of these patients.

References

1. Ash LP, Orihel TC. *Atlas of Human Parasitology*, 5th ed. Chicago, IL: ASCP Press: 2007.
2. Centers for Disease Control and Prevention, Division of Parasitic Diseases (DPD). *Laboratory Identification of Parasites of Public Concern*. <http://www.cdc.gov/dpdx>
3. Garcia LS. 2007. *Diagnostic Medical Parasitology*, 5th ed., Washington, DC. ASM Press..



Attestation of Participation for Self-Reported Training*

We the participants below have completed the review of the CAP BP-B 2017 Participant
Product Mailing, Year

Summary/Final Critique report, and can self report the recommended 0.5 hours towards
Education Hours

fulfilling education and certification of maintenance requirements.

Participant	Date	Participant	Date
_____	_____	_____	_____
_____	_____	_____	_____
_____	_____	_____	_____
_____	_____	_____	_____

Director (or Designee) Signature - I have verified that the individuals listed Date
above have successfully participated in this activity.

Retain this page for record-keeping and auditing purposes.

Individuals can also track their participation of educational activities through the CAP Learning Management System (LMS).

1. Log in to www.cap.org, using your User ID and Password. If you don't have an online account, you will need to create one.
2. Click **Learning**, select **Learning Transcript**
3. Click **'Add My Own Activity'**
4. Enter the required information, and click **Save** when complete

For assistance, call our Customer Contact Center at 800-323-4040 or 847-832-7000 option 1.

**CAP Self-Reported Training activities do not offer CE credit, but can be used towards fulfilling requirements for certification of maintenance by agencies such as the American Society of Clinical Pathology (ASCP). Please verify with your certifying agency to determine your education requirements.*