
COLECTOMY (TME) NEOPLASTIC

RA.SP.PR.GR.GI.06.r07

-
- I. Purpose**
To provide a procedure for the dissection of a total mesorectal excision specimen done for carcinoma of the rectum.
- II. Principle**
To take histologic sections using whole mount (macro) cassettes to demonstrate the pathologic process so that a diagnosis can be made microscopically. All margins and all lymph nodes should be examined. The quality of the mesorectal excision should be assessed.
- III. Equipment**
1. Ruler
 2. Forceps
 3. Scalpel
 4. Scissors
 5. Large knife
- IV. Special Safety Precautions**
1. PPE should be worn.
 2. 10% FORMALIN is a known carcinogen.
- V. Supplies and Reagents**
1. 10% NEUTRAL BUFFERED FORMALIN (pH range 6.9-7.2)
 2. Black Ink
 3. Blue Ink
 4. Green Ink
 5. Orange Ink
 6. Yellow Ink
 7. White Distilled Vinegar
- VI. Quality Control**
All remaining tissue should be retained in accordance with CAP requirements.

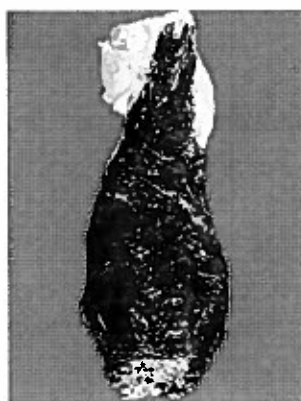COLECTOMY (TME) NEOPLASTIC

VII. Limitations/Notes

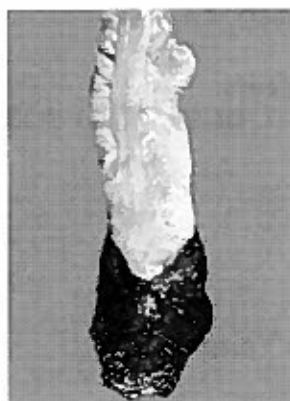1. Grossing of these specimens is restricted to the Pathologists' Assistant or 3rd/4th year residents only (with available oversight by pathologist and/or PA)
2. The specimen should be pinned out and fixed in formalin for at least 24 hours.

VIII. Procedure

1. Assess the quality of the mesorectum and include in dictation.
 - A. Incomplete
 - Little bulk to the mesorectum
 - Defects in the mesorectum down to the muscularis propria
 - After transverse sectioning the circumferential margin appears very irregular
 - B. Nearly Complete
 - Moderate bulk to the mesorectum
 - Irregularity of the mesorectal surface with defects greater than 5 mm, but none extending to the muscularis propria
 - No areas of visibility of the muscularis propria except at the insertion site of the levator ani muscles
 - C. Complete
 - Intact bulky mesorectum with a smooth surface
 - Only minor irregularities of the mesorectal surface
 - No surface defects greater than 5 mm in depth
 - No coning toward the distal margin of the specimen
 - After transverse sectioning the circumferential margin appears smooth



Posterior CRM Inked



Anterior CRM Inked

2. Orient the specimen and ink the posterior radial margin (non-peritonealized area) black, the anterior radial margin (non-peritonealized area) green, the right radial margin (non-peritonealized area) orange, and the left radial margin (non-peritonealized area) blue. If the tumor is more proximal and near a peritonealized surface, ink the peritoneum using a fifth color.

Printed copies of this document are not considered up-to-date. Please verify current version date with online document.

COLECTOMY (TME) NEOPLASTIC

3. Use vinegar as a mordant for the ink.
4. Open the specimen anteriorly.
5. Pin out the specimen and fix for at least 24 hours in formalin.
6. Identify all components of the specimen that are present (ex: sigmoid, rectum, anus, anal skin) and measure each. Include a length and a diameter or an internal circumference (if necessary, give a range of measurements).
7. Describe the specimen using a systematic approach (ex: outside to inside). Carefully inspect the external surface and the mucosa.
8. Describe and measure the neoplastic pathologic process (size, shape, color, & consistency).
9. Serially section the tumor/tumor bed at no more than 5 mm intervals from proximal to distal.
10. Describe the cut surface of the neoplasm and the layers of the colon wall that are involved.
11. Measure the thickness of the neoplasm.
12. Record the distance of the neoplastic process to both the proximal and distal margins.
13. Record whether the tumor is closest to the anterior, posterior or lateral inked radial margin and record the distance.
14. Describe where the neoplasm is in relation to the posterior peritoneal reflection, the anterior reflection (level of Pouch of Douglas on females), and the pectinate line (if present).
15. Submit shave sections of the proximal and distal margins. If the tumor or pathologic process approaches the margin, take perpendicular sections at that margin which may also include the neoplastic process.
16. If there is gross tumor, take a 1 cm superficial section and place in a normal cassette for possible MMR (Mismatch Repair) studies and ink the area on the main specimen that it is taken from.
17. If the specimen has been treated and gross mass/invasion is not seen, submit the entire tumor bed including at least one section proximal, distal, and lateral to the tumor bed in whole mount (macro) cassettes.
18. If there is gross tumor and submitting the entire tumor will exceed five whole mount (macro) cassettes, submit at least three full thickness sections of the tumor or pathologic process at its greatest depth of invasion in whole mount (macro) cassettes.
19. Sample any other grossly identifiable abnormalities.
20. Complete a thorough lymph node search and submit all identifiable lymph nodes.
 - A. For untreated specimens, a minimum of 12 lymph nodes should be found. If 12 lymph nodes are not found, submit an additional 10 cassettes of fat.
 - B. Treated specimens with history of chemoradiation have no lymph node minimum. It is at the discretion of the assigned pathologist to decide on further action (i.e. submitting more fat).
21. All regular tissue cassettes should be processed at the end of the day.
22. All whole mount (macro) cassettes should be placed in formalin and placed on the counter in the embedding room until further processing by histology.

Printed copies of this document are not considered up-to-date. Please verify current version date with online document.

COLECTOMY (TME) NEOPLASTIC

IX. References

1. College of American Pathologists, Cancer Protocols and Checklists, Colon and Rectum (revised July 2008).
2. Hruban RH, Westra, WH, Phelps, PH, & Isacson, C: Surgical Pathology Dissection An Illustrated Guide, New York, NY, Springer-Verlag Inc., 1996.
3. Lester, SC: Manual of Surgical Pathology, New York, NY, Churchill Livingstone, 2001.
4. Parfitt, JR, Driman, DK: The total mesorectal excision specimen for rectal cancer: a review of its pathological assessment. Journal of Clinical Pathology 2007; 60:849-855.

X. Authorized Reviewers

1. Medical Director, Anatomic Pathology
2. Chief, Surgical Pathology

XI. Document Control

Location of Master: Master electronic file stored on the Beaumont Laboratory server under S:\AP_Grossing_Manual

Number of Controlled Copies posted for educational purposes: 0


Number of circulating Controlled Copies: 1

Location of circulating Controlled Copies: Master Grossing Manual located in Surgical Pathology

Printed copies of this document are not considered up-to-date. Please verify current version date with online document.

COLECTOMY (TME) NEOPLASTIC

Document History

Signature	Date	Revision #		Related Documents Reviewed/ Updated
Prepared by: <i>Anne Tranchida PA(ASCP)</i>	6/18/2007	r00		
Approved by: <i>Ali-Reza Armin, MD</i>	11/28/2007	r00		
Reviewed by: (Signature)	Date	Revision #	Modification	Related Documents Reviewed/ Updated
<i>Ali-Reza Armin, MD</i>	12/10/2008	r00		
Revised by: <i>Anne R. Tranchida, PA(ASCP)</i>	1/20/2009	r01	Added to assess the quality of the mesorectum	
<i>Ali-Reza Armin, MD</i>	10/24/2009	r01		
<i>Ali-Reza Armin, MD</i>	10/20/2011	r01		
<i>Ali-Reza Armin, MD</i>	4/03/2013	r01		
<i>Mitual B. Amin, MD</i>	2/14/2015	r01		
<i>Zhenhong H. Qu, MD</i>	3/19/2015	r01		
<i>Kurt Bernacki, MD</i>	10/27/2017	r01		
Revised by: Heather Genson, HTL(ASCP) ^{CM} PA ^{CM}	11/30/2018	r02	Removed formalin alcohol and added taking a superficial section of mass prior to macro cassettes	
Approved by: <i>Kurt Bernacki, MD</i>	11/30/2018	r02		
Revised by: Heather Genson, HTL(ASCP) ^{CM} PA ^{CM}	12/13/2018	r03	Added to take gross photos of mesorectum at triage	
Approved by: <i>Kurt Bernacki, MD</i>	12/13/2018	r03		
Revised by: Heather Genson, HTL(ASCP) ^{CM} PA ^{CM}	5/16/2019	r04	Removed taking gross photos of mesorectum at triage	
Approved by: <i>Kurt Bernacki, MD</i>	5/16/2019	r04		
<i>Kurt Bernacki, MD</i>	10/22/2019	r04		
Revised by: Heather Genson, HTL(ASCP) ^{CM} PA ^{CM}		r05	Revised procedure to decrease macro cassettes submitted	
Approved by: <i>Kurt Bernacki, MD</i>	5/20/2021	r05		
<i>Jawwad Arshad, MD</i>	3/20/2023	r05		
Revised by: <i>Heather Genson, HTL(ASCP)^{CM}PA^{CM}</i>	9/18/2024	r06	Added minimum number of lymph nodes	
Approved by: <i>Laura Walters, MD, PhD</i>	9/18/2024	r06		
Revised by: <i>Heather Genson, HTL(ASCP)^{CM}PA^{CM}</i>	1/22/2025	r07	Added limitation that grossing is restricted to PA or 3 rd /4 th year resident	
Approved by: 	2/14/25			

Printed copies of this document are not considered up-to-date. Please verify current version date with online document.

COLECTOMY (TME) NEOPLASTIC

Document History Continued

Reviewed by: (Signature)	Date	Revision #	Modification	Related Documents Reviewed/ Updated

Printed copies of this document are not considered up-to-date. Please verify current version date with online document.