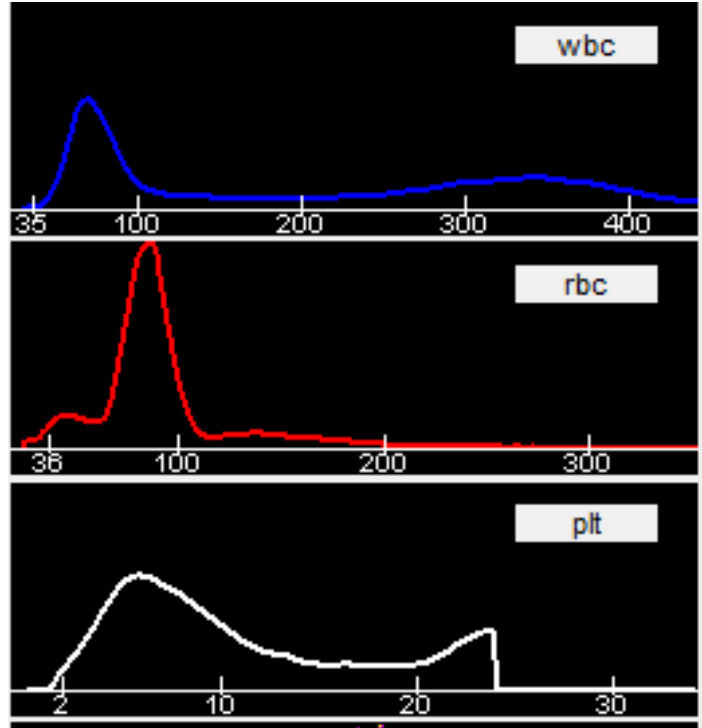
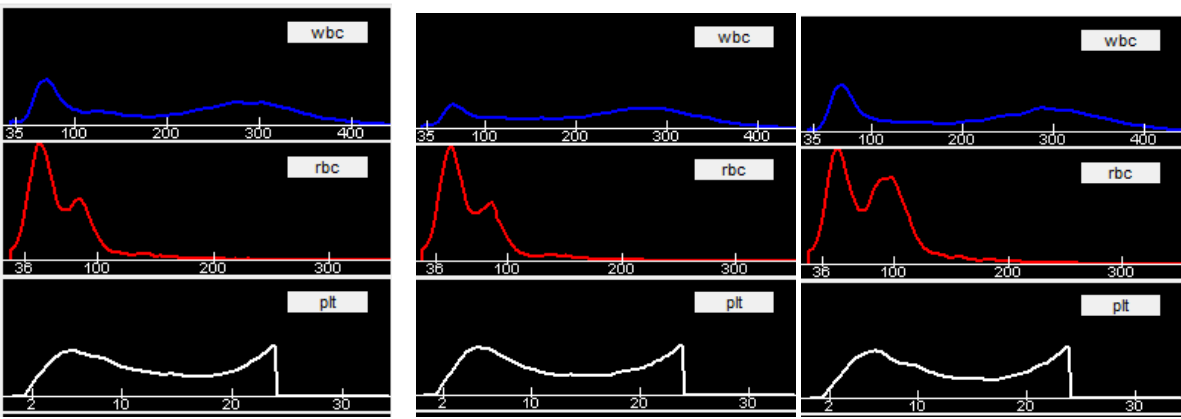
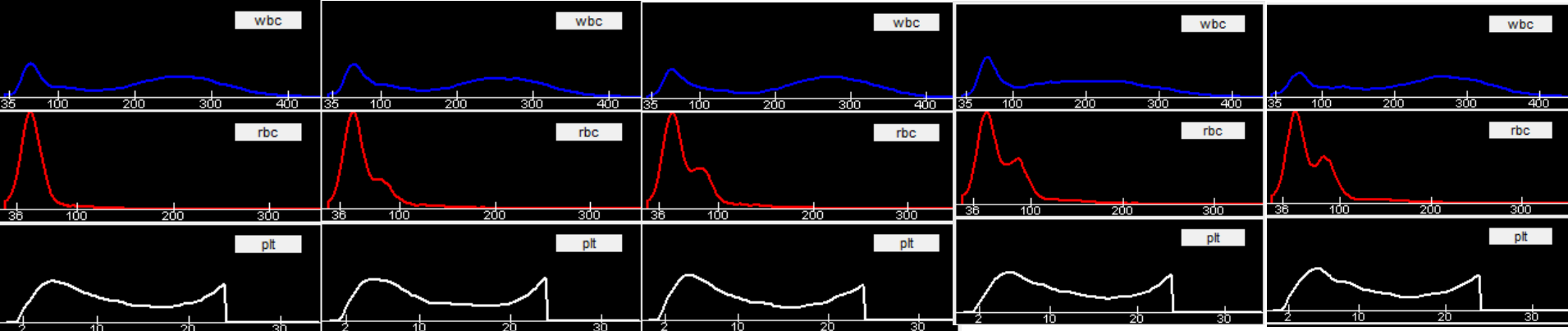


Haematology	25-10-2019 13:30	06-09-2019 10:20	28-08-2019 09:32	27-08-2019 11:58	25-08-2019 11:03	24-08-2019 22:30	24-08-2019 16:38	24-08-2019 10:42	23-08-2019 21:55
FBE									
<input type="checkbox"/> Hb	150	111	78	80	76	72	67	58	43
<input type="checkbox"/> WBC	5.46	4.10	2.63	4.16	4.95	6.60	5.36	4.47	4.98
<input type="checkbox"/> Platelets	204	208	225	267	245	246	265	257	295
<input type="checkbox"/> Hct	0.44	0.36	0.25	0.26	0.24	0.23	0.22	0.19	0.16
<input type="checkbox"/> MCV	83	75	64	63	63	64	61	58	52
<input type="checkbox"/> MCH	28.4	23.5	20.0	19.6	20.1	19.9	18.4	17.6	13.8
<input type="checkbox"/> MCHC	344	313	315	309	316	311	301	302	266
<input type="checkbox"/> RBC	5.29	4.75	3.89	4.07	3.76	3.61	3.64	3.28	3.10
<input type="checkbox"/> RDW	13.1	40.7	36.0	35.8	35.0	35.5	33.6	31.1	21.3
<input type="checkbox"/> Neutrophils	2.52	2.26	1.57	2.32	3.04	3.69	3.51	2.50	2.94
<input type="checkbox"/> Lymphocytes	2.04	1.15	0.53	1.19	1.05	1.90	1.15	1.28	1.37
<input type="checkbox"/> Monocytes	0.51	0.38	0.40	0.53	0.75	0.82	0.61	0.57	0.56
<input type="checkbox"/> Eosinophils	0.28	0.17	0.05	0.05	0.05	0.06	0.02	0.04	0.01
<input type="checkbox"/> Basophils	0.10	0.14	0.08	0.07	0.06	0.13	0.07	0.09	0.11
Morphology	* Comment								* (c) Comment
FBE Phone Comment								Phoned Commer	Phoned Commer

Why am I even looking at the blood film from 25/10/2019 ?



Top left to bottom right = progression of iron therapy.

Note last scatter has RDW of 13.1 and the analyser has ignored the microcytic population of red cells.

Comments : Red cells show a dimorphic picture with a mild increase in microcytes and hypochromic cells. The normal RDW appears to be analyser artifact. White cells and platelets appear normal. History of iron deficiency noted. Performed