

CASE STUDIES

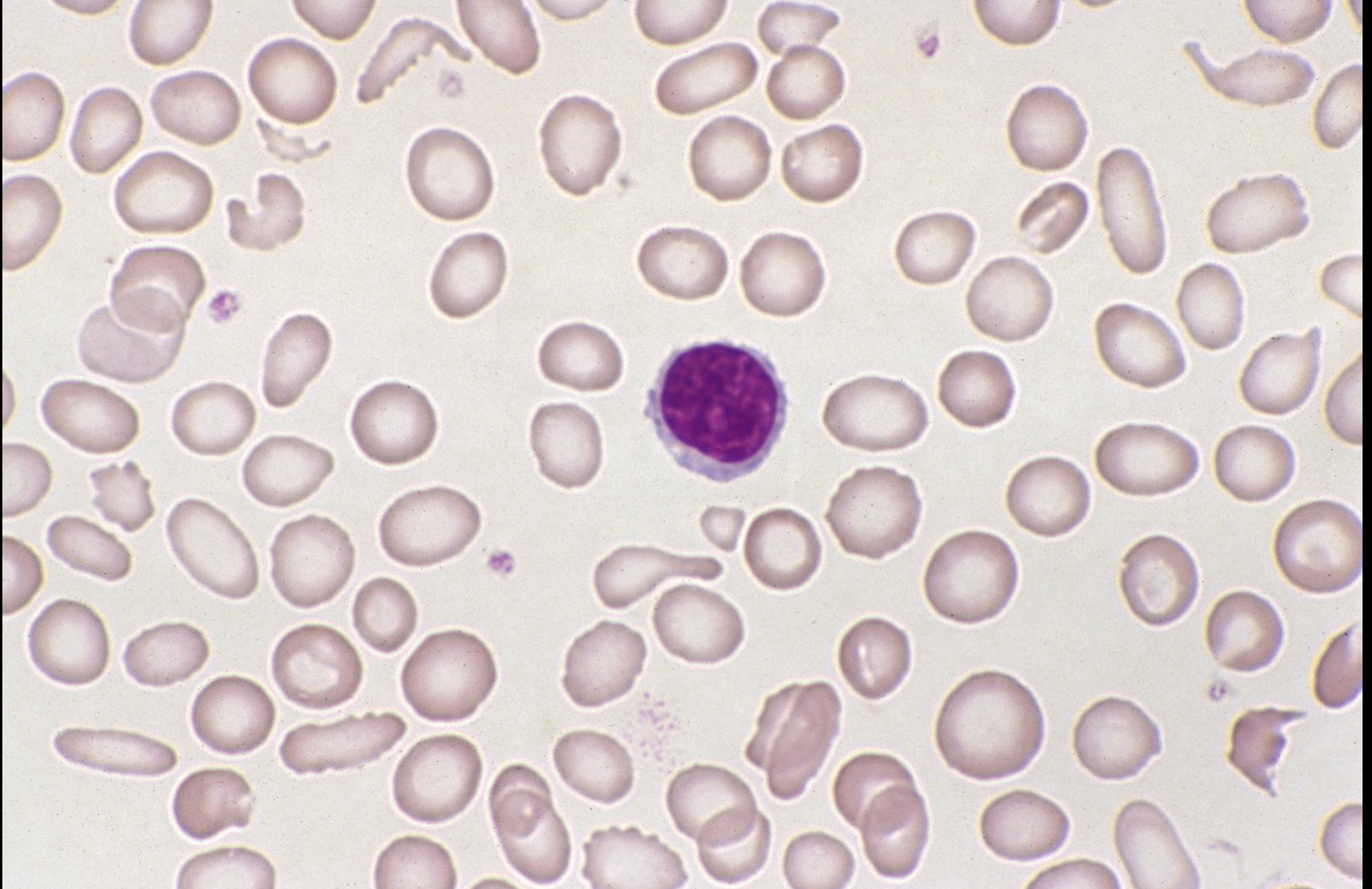GILLIAN ROZENBERG
TRAINING WORKSHOPS

CASE STUDY

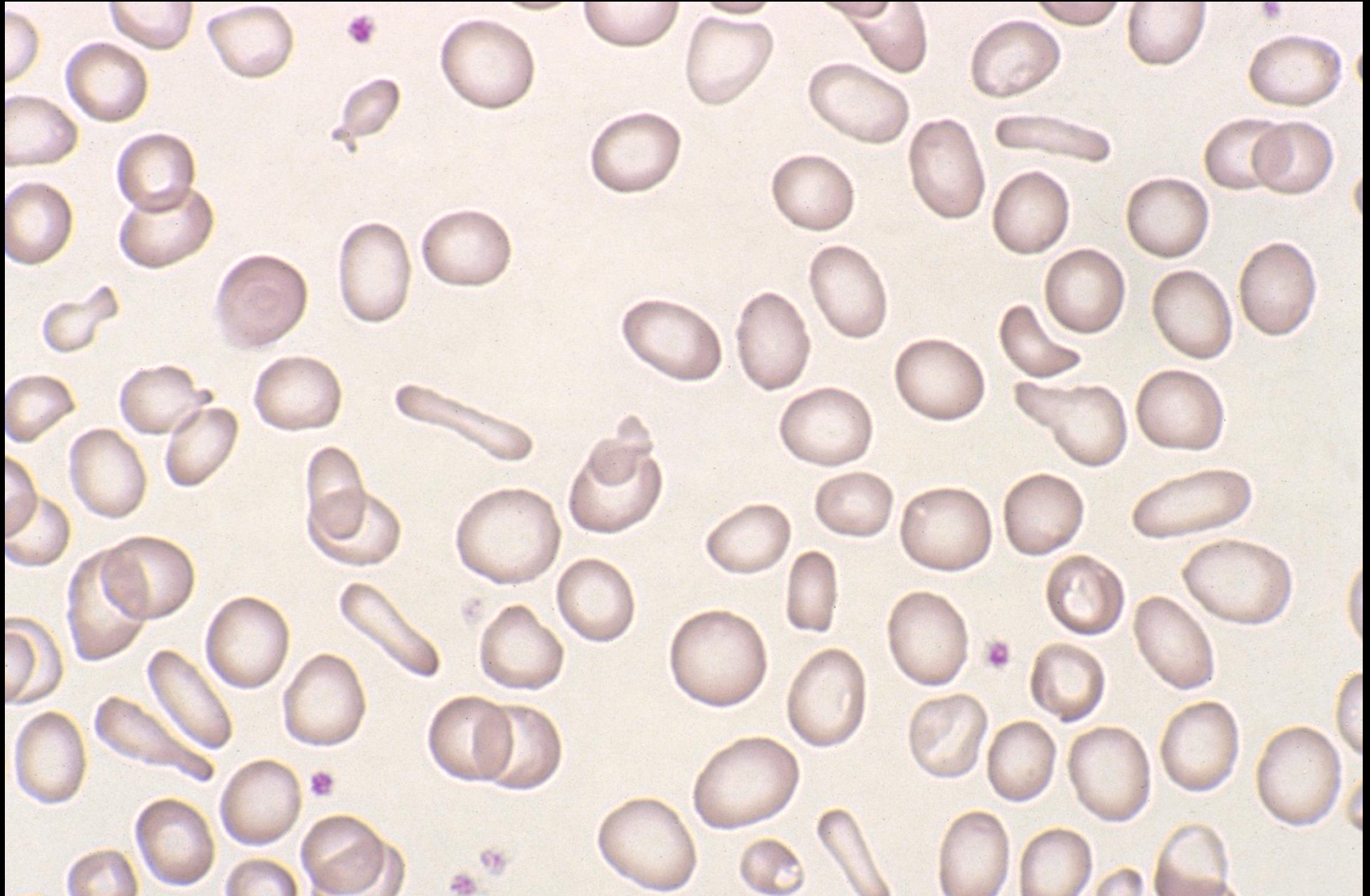
Female 30 years: Menorrhagia

• Hb	60	(115-165)	g/L
• RBC	4.32	(3.80-5.80)	$\times 10^{12}/L$
• MCV	58.3	(80-100)	fL
• MCH	13.9	(26.5-33.0)	pg
• MCHC	238	(310-360)	g/L
• RDW-CV	16.5	(12.0-14.5)	%
• WBC	8.9	(3.50-11.00)	$\times 10^9/L$
• Plats	438	(150-400)	$\times 10^9/L$

Case study (1)



Case study (1)



CASE STUDY

Blood film comments:

Slight anisocytosis

Marked microcytes

Marked hypochromasia

Slight elliptocytes

Slight pencil cells

Thrombocytosis

CASE STUDY

Iron studies:

Iron	1.7	(5-30.4)	umol/L
Transferrin	4.2	(1.9-2.8)	g/L
Iron saturation	1.6	(16-51)	%
Ferritin	2	(15-200)	ug/L

CASE STUDY

DIAGNOSIS:

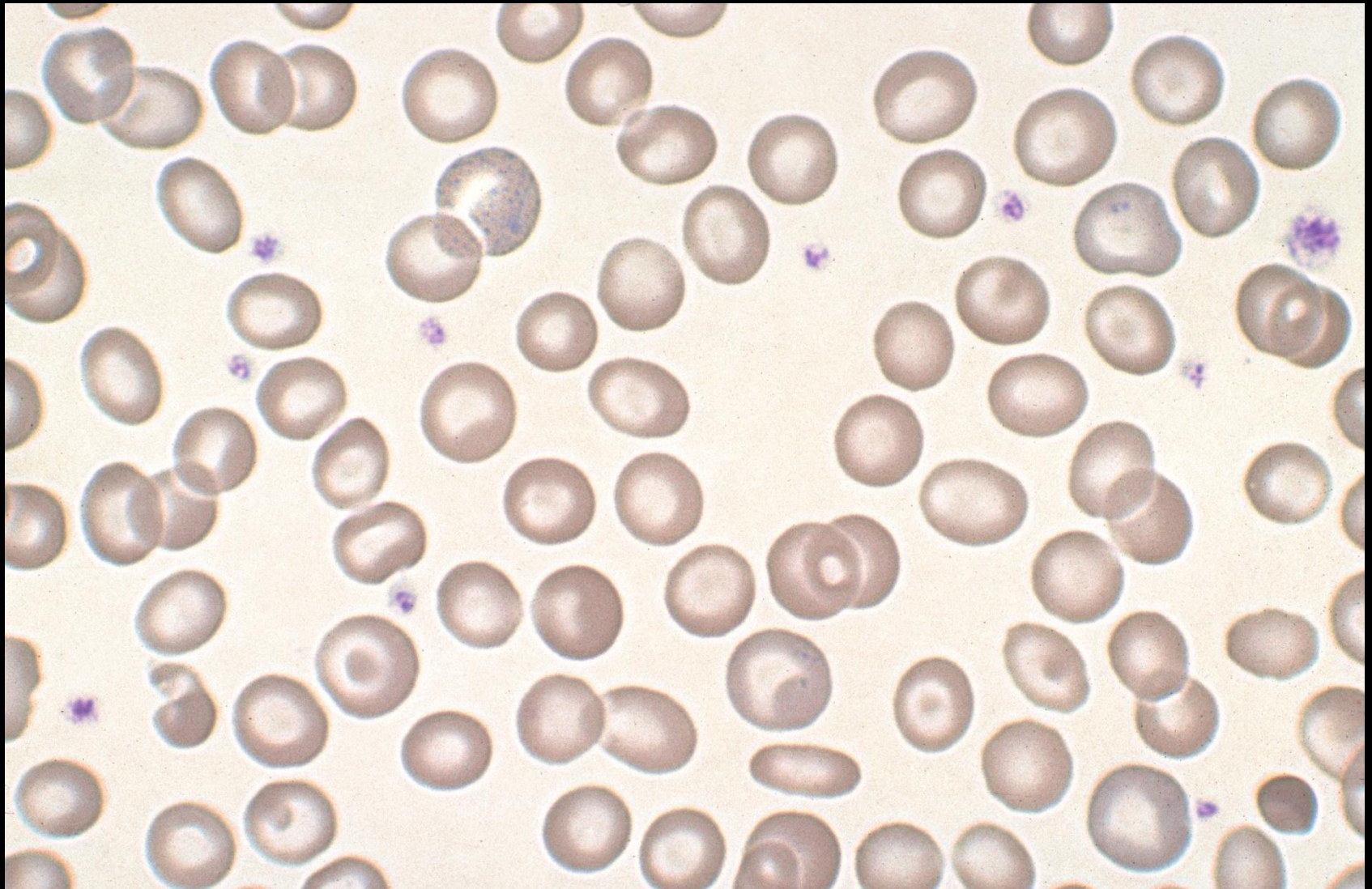
- Fe deficiency anaemia

CASE STUDY

Female 34 years: Immigrant from Greece

• Hb	102	(115-165)	g/L
• RBC	5.91	(3.80-5.80)	$\times 10^{12}/L$
• MCV	69.2	(80-100)	fL
• MCH	21.7	(26.5-33.0)	pg
• MCHC	313	(310-360)	g/L
• RDW-CV	14.3	(12.0-14.5)	%
• WBC	9.01	(3.50-11.00)	$\times 10^9/L$
• Plats	204	(150-400)	$\times 10^9/L$

Case study (2)



CASE STUDY

Blood film comments:

Slight microcytes

Slight hypochromasia

Slight target cells

Slight basophilic stippling

CASE STUDY

Haemoglobin Electrophoresis:

Hb EPG Cellulose Acetate (pH 8.6)

Hb A2	5.4 %	NR 2.0 – 3.5
-------	-------	--------------

Hb F	<1 %	NR <1
------	------	-------

Hb H inclusions		Not detected
-----------------	--	--------------

CASE STUDY

DIAGNOSIS:

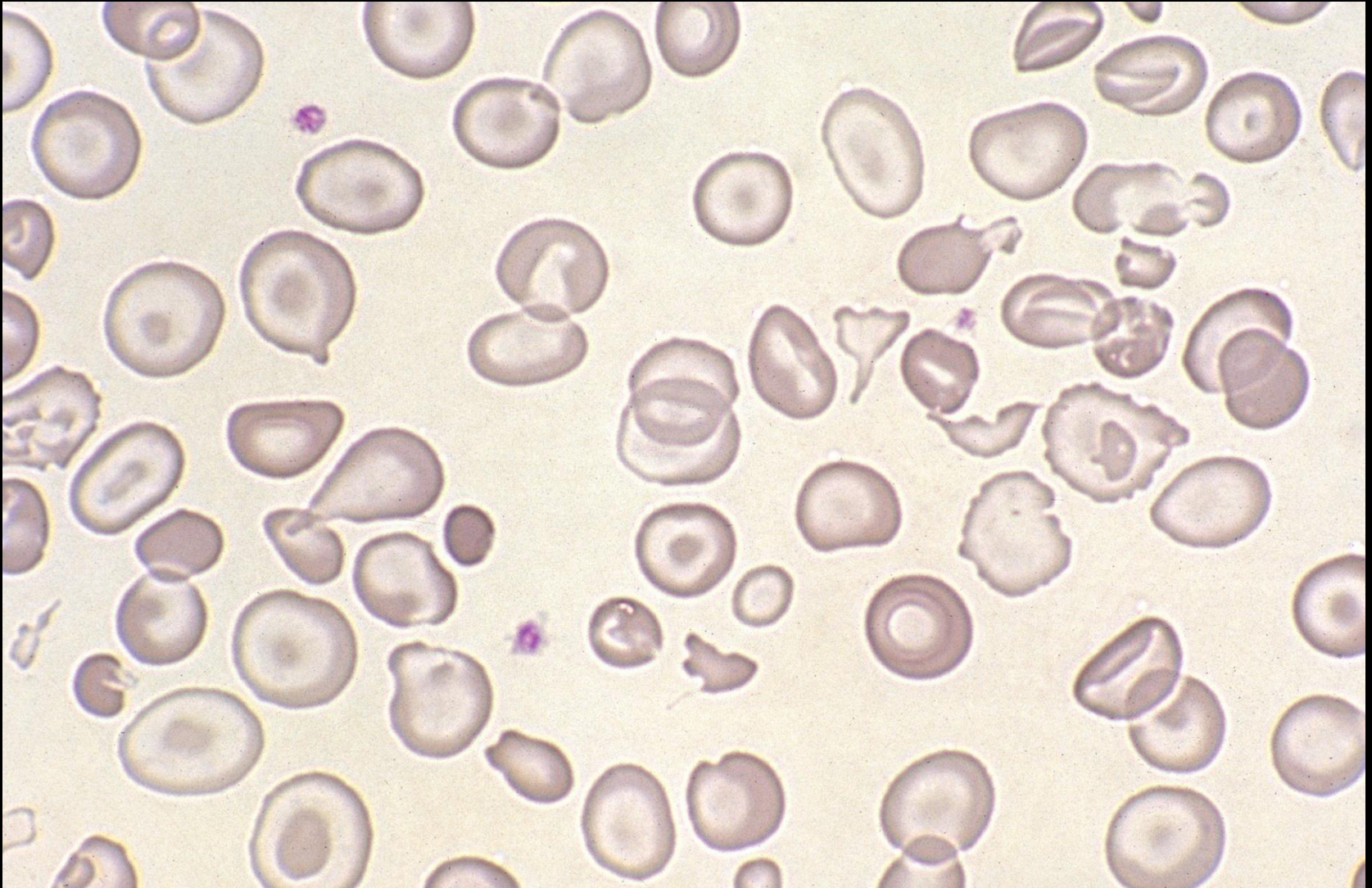
- β thalassaemia trait

CASE STUDY

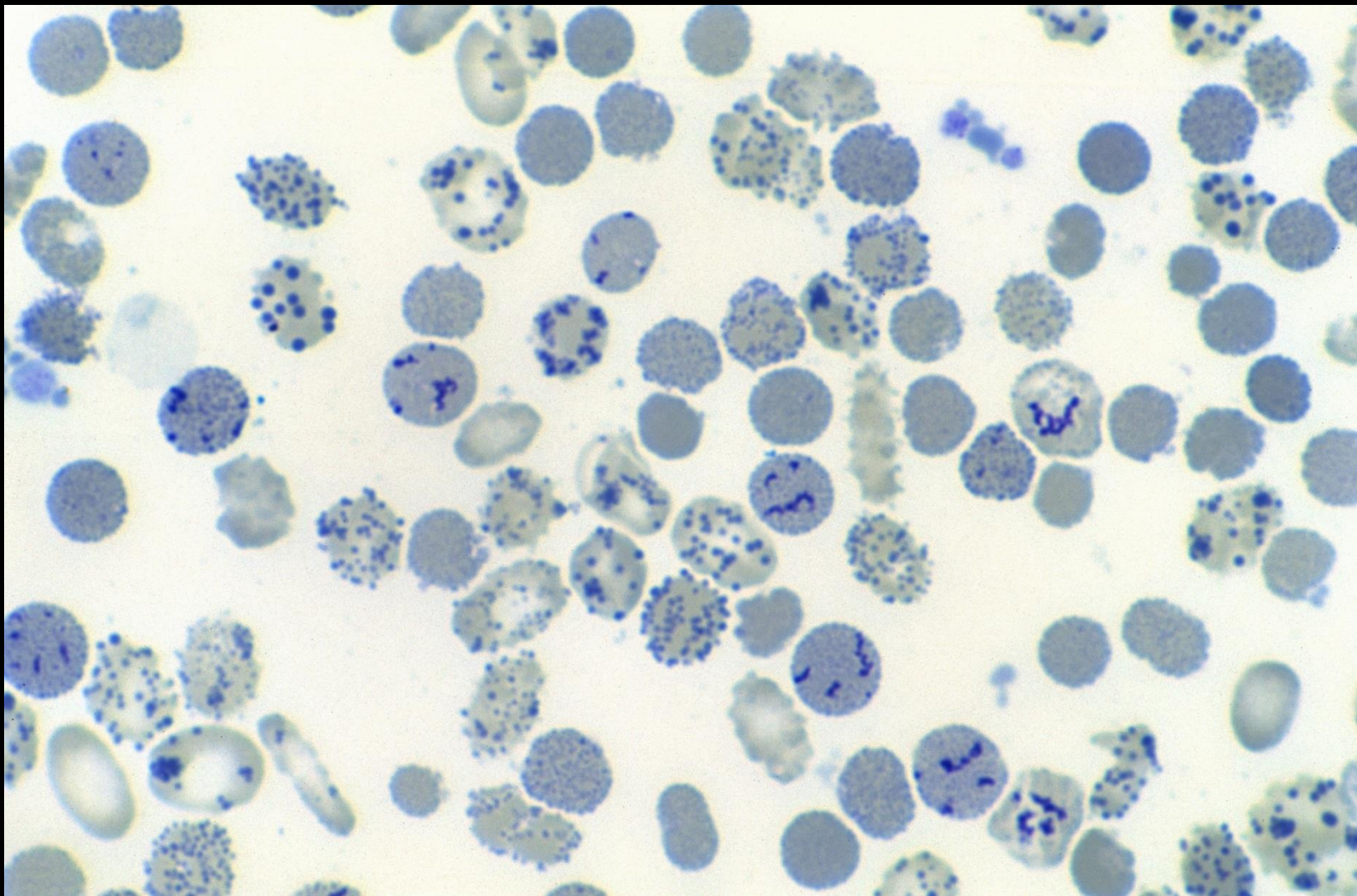
Female 66 years: Immigrant from Asia

• Hb	87	(115-165)	g/L
• RBC	6.39	(3.80-5.80)	$\times 10^{12}/L$
• MCV	54.9	(80-100)	fL
• MCH	16.1	(26.5-33.0)	pg
• MCHC	293	(310-360)	g/L
• RDW-CV	15.9	(12.0-14.5)	%
• WBC	6.4	(3.50-11.00)	$\times 10^9/L$
• Plats	218	(150-400)	$\times 10^9/L$

Case study (3)



Case study (3)



CASE STUDY

Blood film comments:

Slight anisocytosis

Slight microcytes

Slight hypochromasia

Slight polychromasia

Moderate target cells

CASE STUDY

DIAGNOSIS:

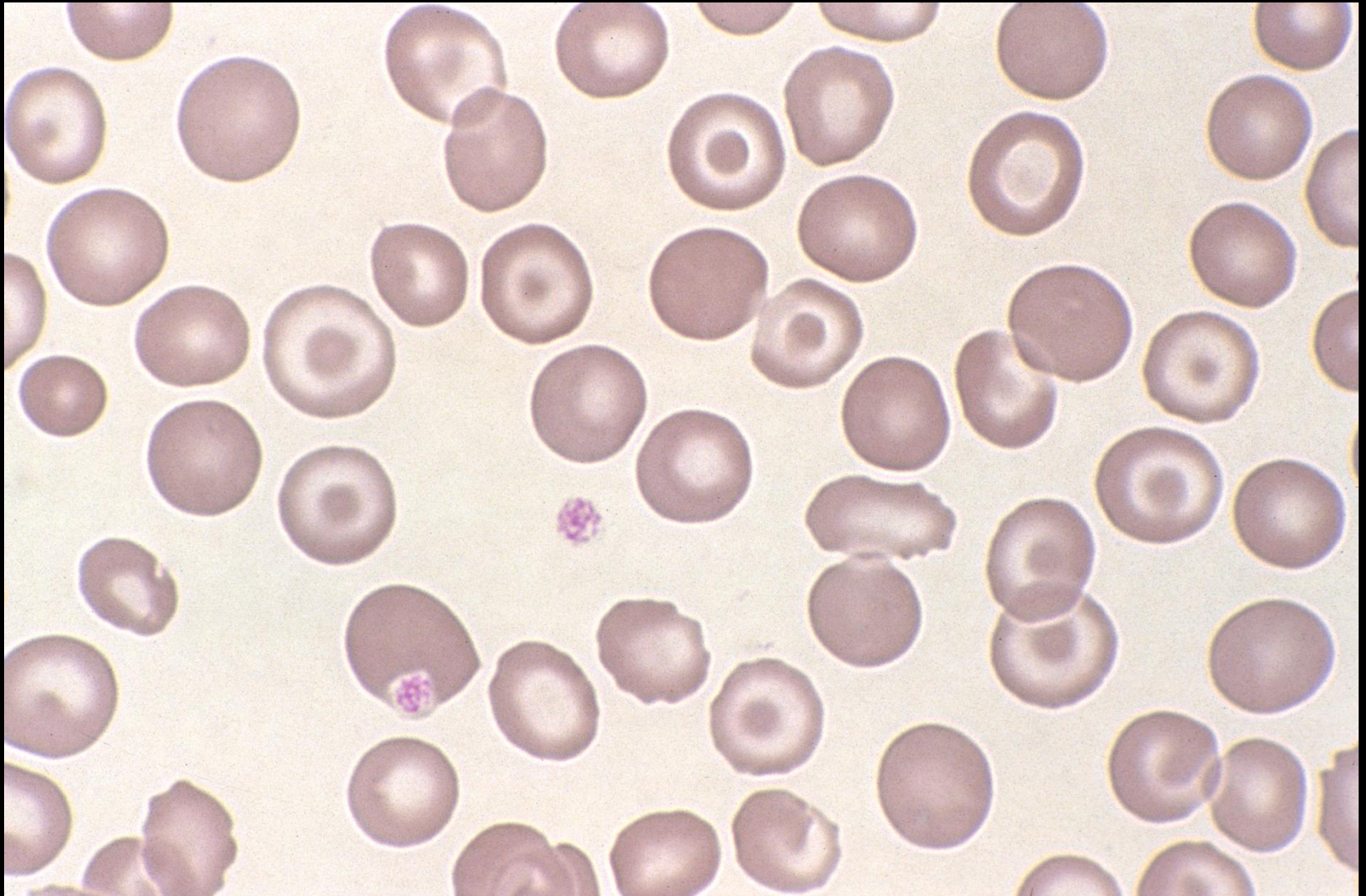
- Hb H disease

CASE STUDY

Male 46 years: Heavy drinker

• Hb	151	(130-180)	g/L
• RBC	4.41	(4.50-6.50)	$\times 10^{12}/L$
• MCV	99.8	(80-100)	fL
• MCH	34.2	(26.5-33.0)	pg
• MCHC	343	(310-360)	g/L
• RDW-CV	15.7	(12.0-14.5)	%
• WBC	8.5	(3.50-11.00)	$\times 10^9/L$
• Plats	71	(150-400)	$\times 10^9/L$

Case study (4)



CASE STUDY

Blood film comments:

Slight anisocytosis

Moderate round macrocytes

Moderate target cells

Thrombocytopenia

CASE STUDY

Liver function tests:

• Bilirubin total	20	umol/L	0-25
• ALP	53	U/L	38-126
• ALT	68	U/L	<45
• AST	77	U/L	<45
• GGT	282	U/L	0-50

CASE STUDY

DIAGNOSIS:

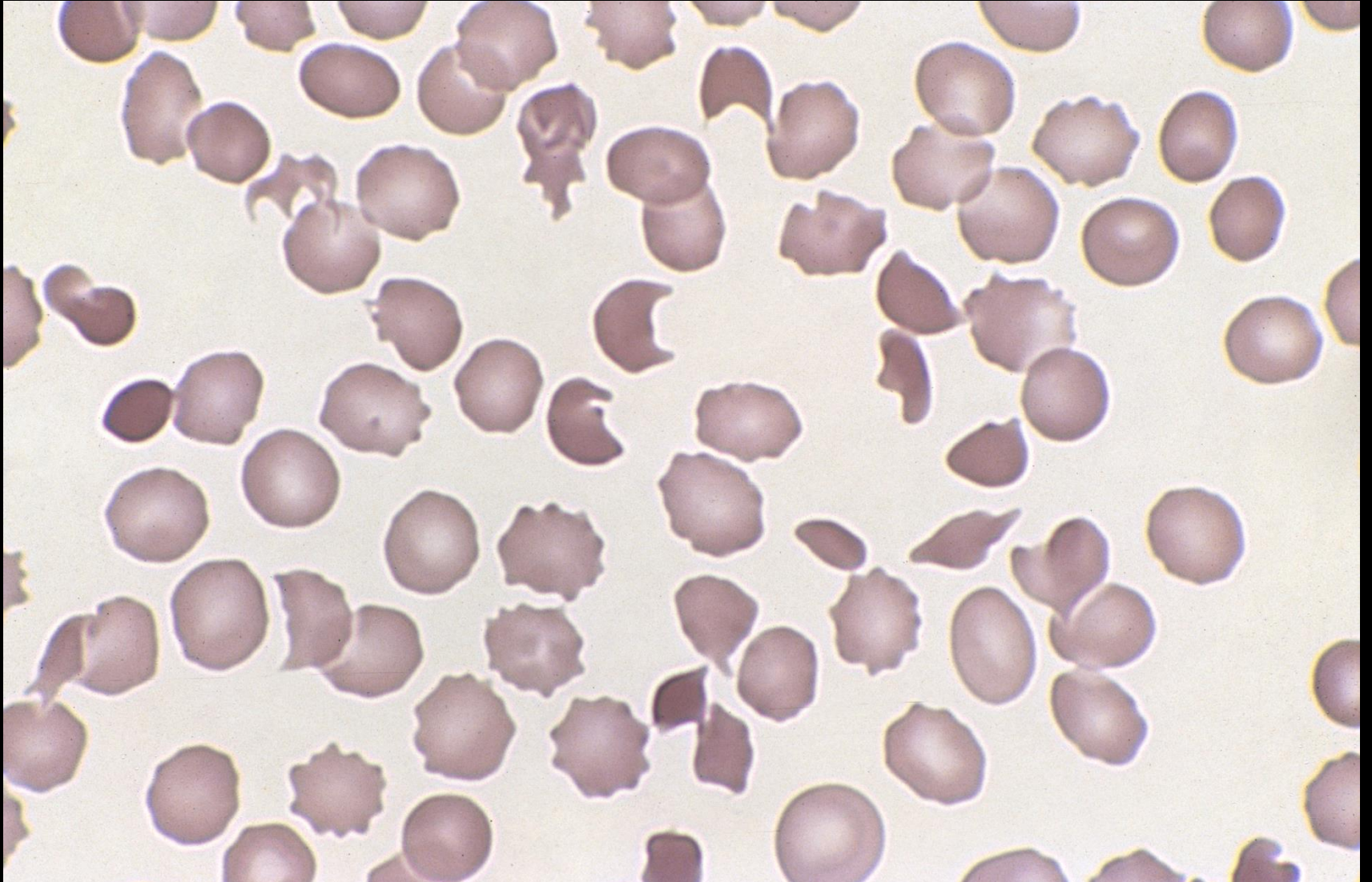
- Alcoholic liver disease

CASE STUDY

Male 18 months: Bloody diarrhoea

• Hb	93	(104-132)	g/L
• RBC	3.21	(3.88-5.13)	$\times 10^{12}/L$
• MCV	83.2	(70-83)	fL
• MCH	29.0	(23.1-29.4)	pg
• MCHC	348	(323-354)	g/L
• RDW-CV	14.1	(12.3-17.0)	%
• WBC	13.5	(5.4-13.6)	$\times 10^9/L$
• Plats	27	(205-553)	$\times 10^9/L$

Case study (5)



CASE STUDY

Blood film comments:

Slight anisocytosis

Slight polychromasia

Moderate schistocytes

Marked thrombocytopenia

Microangiopathic haemolytic anaemia

CASE STUDY

Renal function tests:

- Urea 21.5 mmol/L 2.9-7.1
- Creatinine 278 mmol/L 20-40

CASE STUDY

DIAGNOSIS:

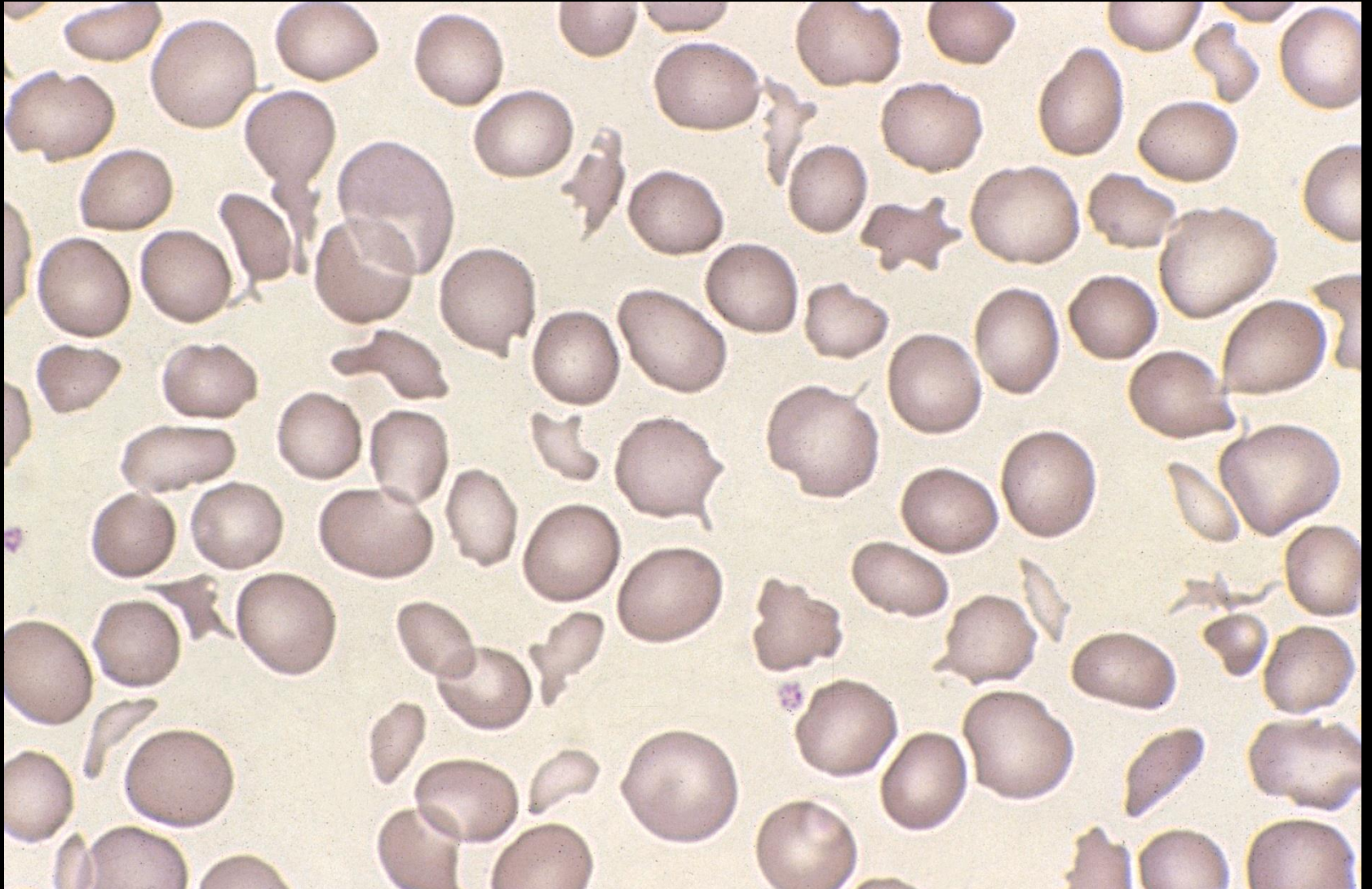
- Microangiopathic haemolytic anaemia:
haemolytic uraemic syndrome (HUS)

CASE STUDY

Female 85 years: Post MVR

• Hb	78	(115-165)	g/L
• RBC	2.44	(3.80-5.80)	$\times 10^{12}/L$
• MCV	95.5	(80-100)	fL
• MCH	32.0	(26.5-33.0)	pg
• MCHC	335	310-360)	g/L
• RDW-CV	15.6	(12.0-14.5)	%
• WBC	11.1	(3.50-11.00)	$\times 10^9/L$
• Plats	242	(150-400)	$\times 10^9/L$

Case study (6)



CASE STUDY

Blood film comments:

Slight anisocytosis

Slight polychromasia

Moderate schistocytes

Normal platelet count

Microangiopathic haemolytic anaemia

CASE STUDY

DIAGNOSIS:

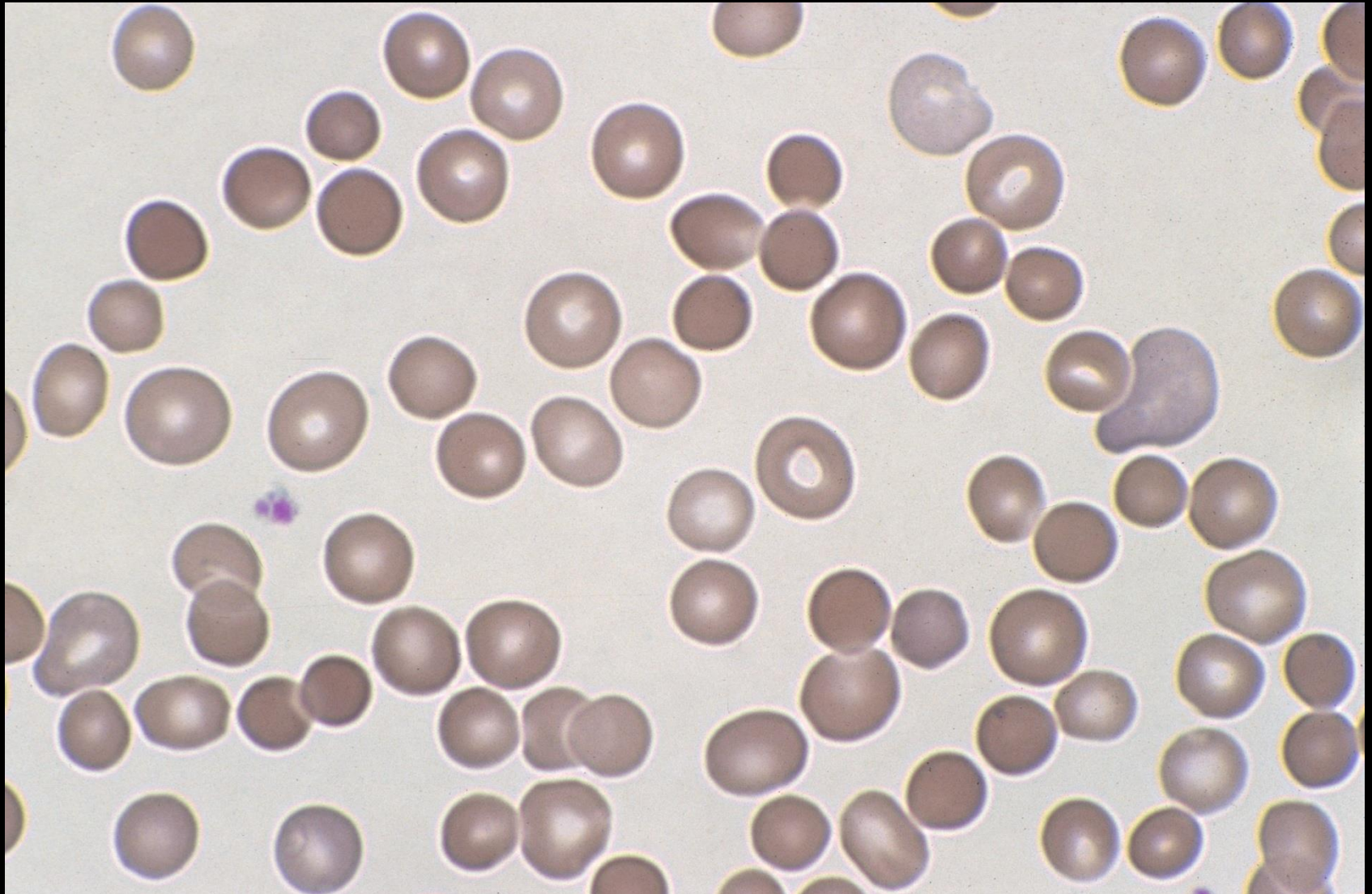
- Microangiopathic haemolytic anaemia:
heart valve haemolysis

CASE STUDY

Female 22 years: ?gall stones

• Hb	134	(115-165)	g/L
• RBC	3.87	(3.80-5.80)	$\times 10^{12}/L$
• MCV	91.5	(80-100)	fL
• MCH	34.6	(26.5-33.0)	pg
• MCHC	365	(310-360)	g/L
• RDW-CV	14.8	(12.0-14.5)	%
• WBC	8.4	(3.50-11.00)	$\times 10^9/L$
• Plats	377	(150-400)	$\times 10^9/L$

Case study (7)



CASE STUDY

Blood film comments:

Slight anisocytosis

Slight polychromasia

Moderate spherocytes

CASE STUDY

Reticulocyte count:

- Retic 4.2% 0.2–2.0
- Retic Abs. $162.5 \times 10^9/L$ 10-100

- DAT: Negative

CASE STUDY

DIAGNOSIS:

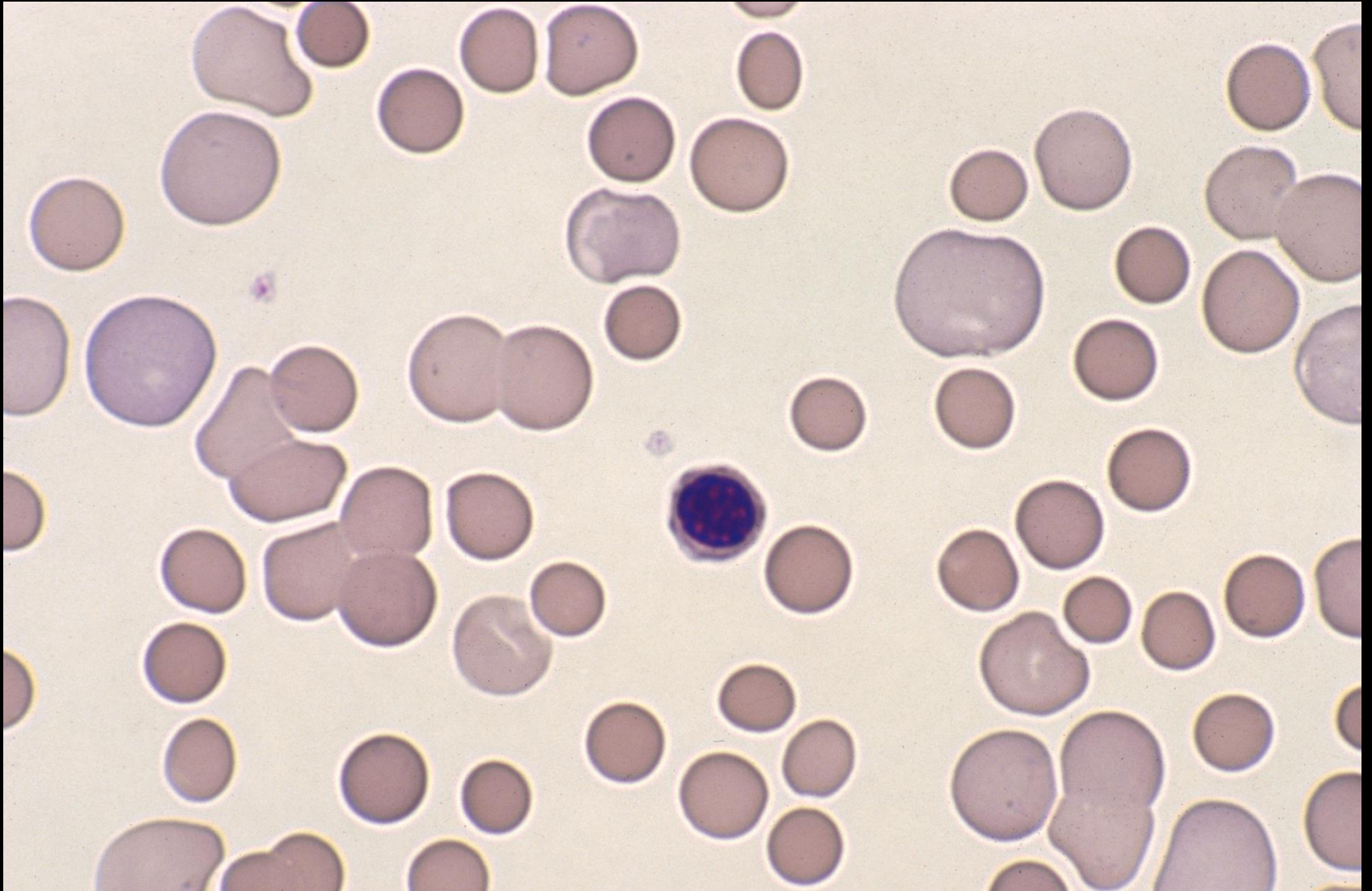
- Hereditary spherocytosis

CASE STUDY

Female 46 years: Jaundice for investigation

• Hb	56	(115-165)	g/L
• RBC	1.80	(3.80-5.80)	$\times 10^{12}/L$
• MCV	97.0	(80-100)	fL
• MCH	33.2	(26.5-33.0)	pg
• MCHC	331	(310-360)	g/L
• RDW-CV	15.8	(12.0-14.5)	%
• WBC	24.0	(3.50-11.00)	$\times 10^9/L$
• Plats	195	(150-400)	$\times 10^9/L$

Case study (8)



CASE STUDY

Blood film comments:

Slight anisocytosis

Moderate polychromasia

Moderate spherocytes

53 NRBC's / 100 WBC's

CASE STUDY

Reticulocyte count:

- Retic 8.1% 0.2–2.0
- Retic Abs. 272.0 x 10⁹/L 10-100
- **DAT:** Positive (IgG)

CASE STUDY

DIAGNOSIS:

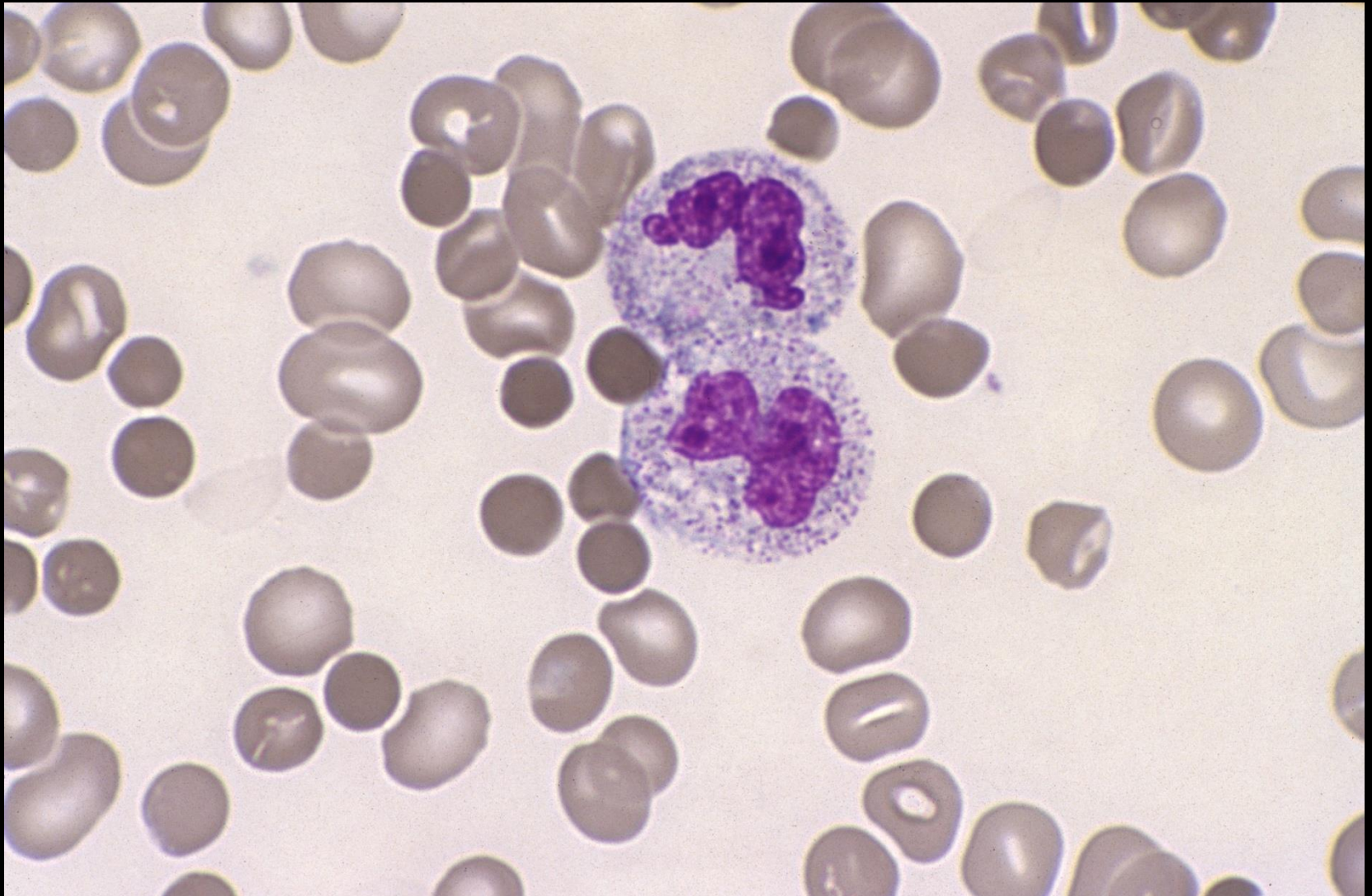
- Auto immune haemolytic anaemia

CASE STUDY

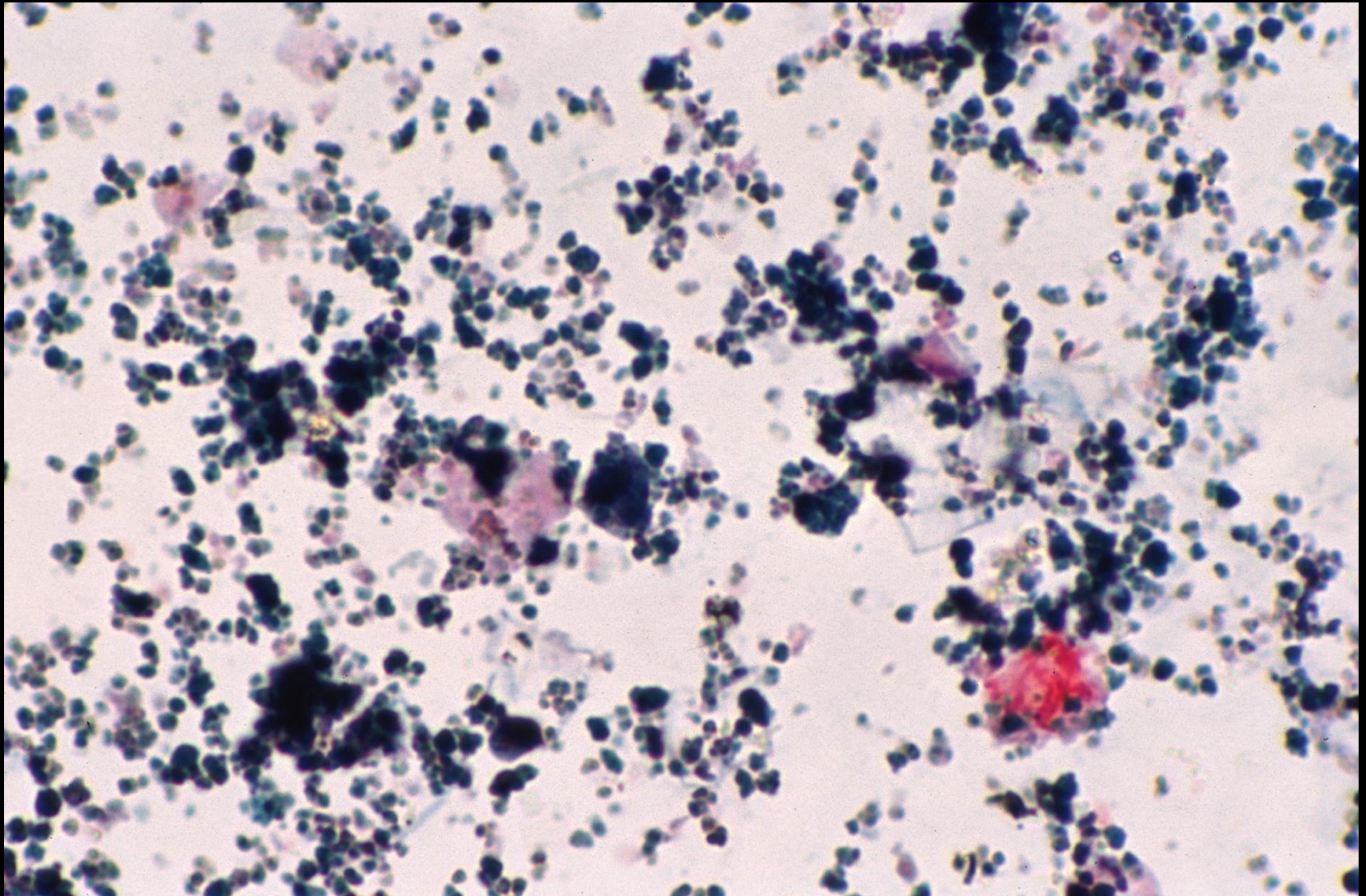
Female 56 years: Necrotizing fasciitis

• Hb	75	(115-165)	g/L
• RBC	2.42	(3.80-5.80)	$\times 10^{12}/L$
• MCV	93.4	(80-100)	fL
• MCH	31.0	(26.5-33.0)	pg
• MCHC	332	(310-360)	g/L
• RDW-CV	16.8	(12.0-14.5)	%
• WBC	14.4	(3.50-11.00)	$\times 10^9/L$
• Plats	163	(150-400)	$\times 10^9/L$

Case study (9)



Case study (9)
Urinary haemosiderin (Perl's stain)



CASE STUDY

Blood film comments:

Moderate toxic granulation

Slight anisocytosis

Moderate spherocytes

Slight rouleaux

CASE STUDY

Reticulocyte count:

- Retic 2.4% 0.2–2.0
- Retic Abs. 35.2 x 10⁹/L 10-100

Coagulation studies:

PT	23.4 sec	12.0-15.0
INR	2.1	0.8-1.1
APTT	47.1 sec	25.0-35.0

CASE STUDY

Chemistry results:

LD	1936 IU/L	90-200
----	-----------	--------

Urea	11.1 mmol/L	2.9-7.1
------	-------------	---------

Creatinine	206 umol/L	60-110
------------	------------	--------

Bilirubin total	507 umol/L	0-25
-----------------	------------	------

ALP	48 U/L	38-126
-----	--------	--------

GGT	10 U/L	0-30
-----	--------	------

AST	2550 U/L	<45
-----	----------	-----

ALT	590 U/L	<45
-----	---------	-----

CASE STUDY

DIAGNOSIS:

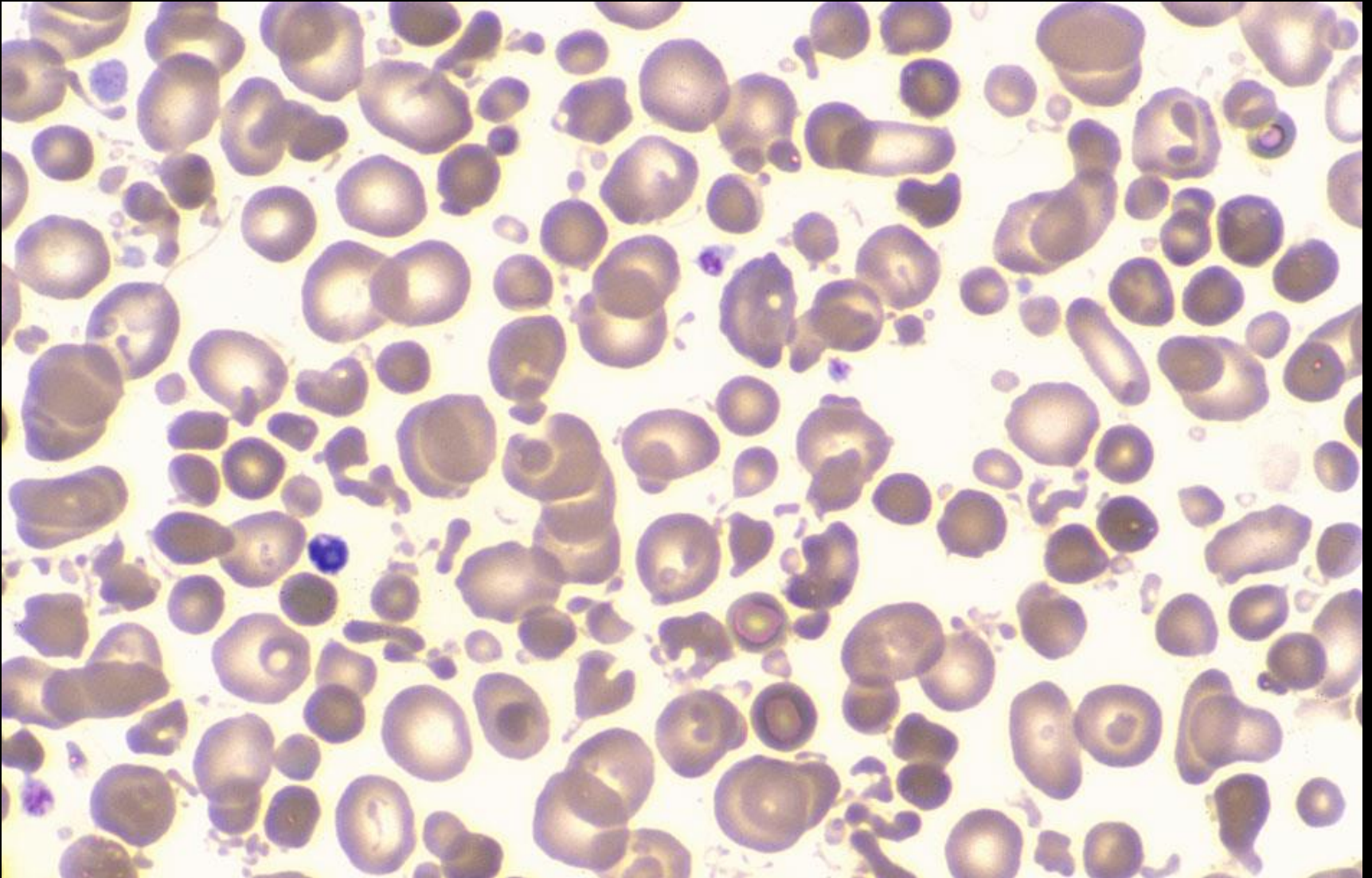
- *Clostridium perfringens* – induced haemolytic anaemia

CASE STUDY

Male 8 years: Emergency admission to ED

• Hb	118	(113-143)	g/L
• RBC	6.43	(3.98-5.15)	$\times 10^{12}/L$
• MCV	53.3	(75-86)	fL
• MCH	18.4	(25.7-30.6)	pg
• MCHC	344	(335-361)	g/L
• RDW-CV	15.5	(12.0-14.1)	%
• WBC	34.2	(4.7-12.2)	$\times 10^9/L$
• Plats	NR	(187-415)	$\times 10^9/L$

Case study (10)



CASE STUDY

Blood film comments:

Moderate anisocytosis

Moderate microcytes

Moderate hypochromasia

Marked fragments

Marked microspherocytes

Marked red cell budding

CASE STUDY

DIAGNOSIS:

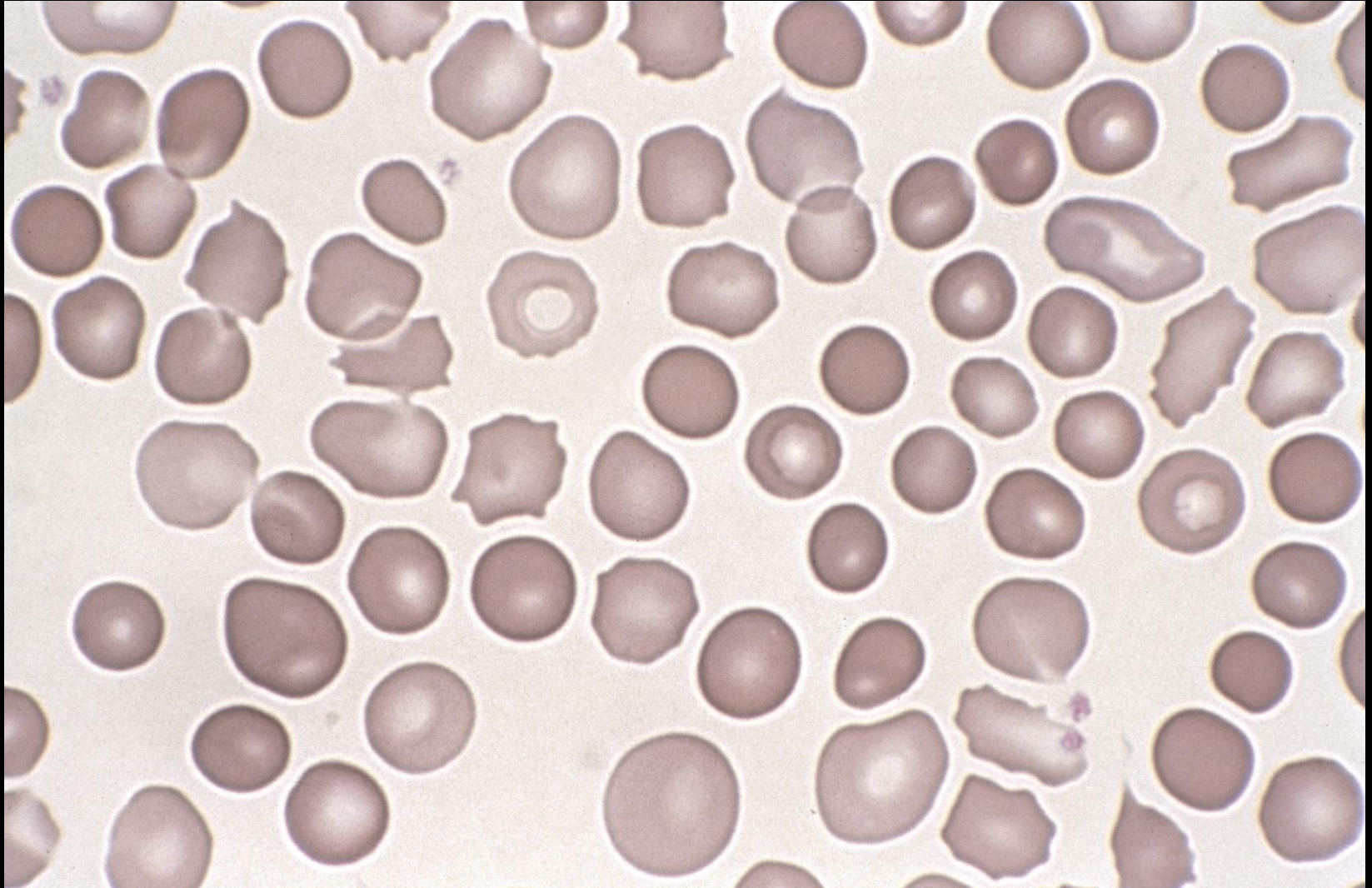
- Third degree burns
- Probable β thalassaemia trait / Fe \downarrow anaemia

CASE STUDY

One day old neonate: Jaundice in first 24 hrs of birth

- Hb 136 (121-191) g/L
- RBC 3.62 (3.34-5.40) x 10¹²/L
- MCV 111.0 (101-117) fL
- MCH 37.6 (33.0-38.0) pg
- MCHC 338 (302-341) g/L
- RDW-CV 16.4 (15.5-19.2) %
- WBC 12.5 (9.6-30.4) x 10⁹/L
- Plats 348 (195-434) x 10⁹/L

Case study (11)



CASE STUDY

Blood film comments:

Slight anisocytosis

Moderate round macrocytes

Moderate polychromasia

Moderate spherocytes

2 NRBC's / 100 WBC's

CASE STUDY

- **Mother:**
Blood group O
- **Neonate:**
Blood group A

DAT: Negative (weakly positive)

CASE STUDY

DIAGNOSIS:

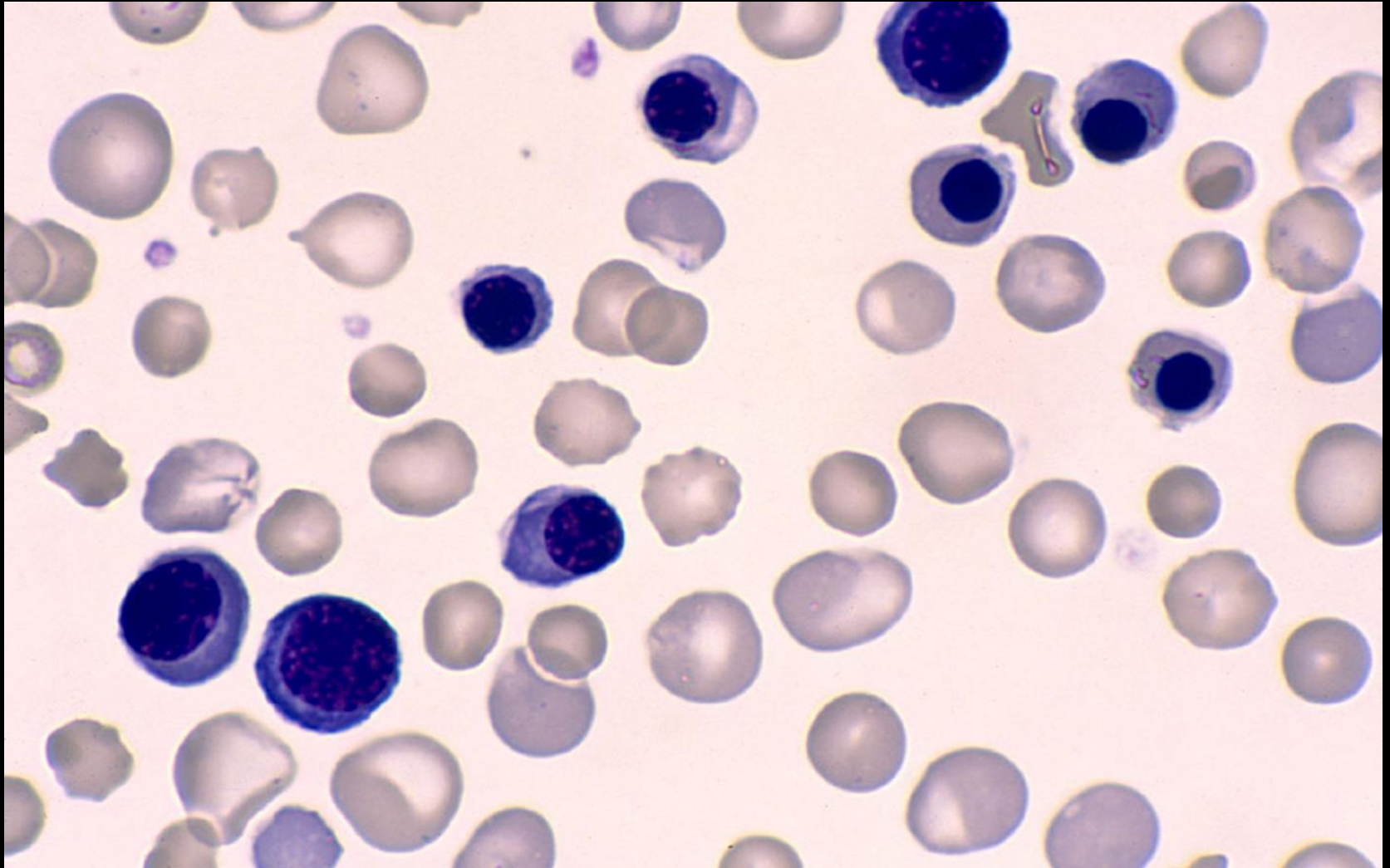
- ABO haemolytic disease of the newborn

CASE STUDY

One day old neonate: Extreme jaundice

• Hb	120	(121-191)	g/L
• RBC	3.62	(3.34-5.40)	$\times 10^{12}/L$
• MCV	140	(101-117)	fL
• MCH	41.3	(33.0-38.0)	pg
• MCHC	339	(302-341)	g/L
• RDW-CV	19.3	(15.5-19.2)	%
• WBC	20.5	(9.6-30.4)	$\times 10^9/L$
• Plats	321	(195-434)	$\times 10^9/L$

Case study 12



CASE STUDY

Blood film comments:

Slight anisocytosis

Moderate round macrocytes

Marked polychromasia

432 NRBC's / 100 WBC's

DAT: Strongly positive

CASE STUDY

DIAGNOSIS:

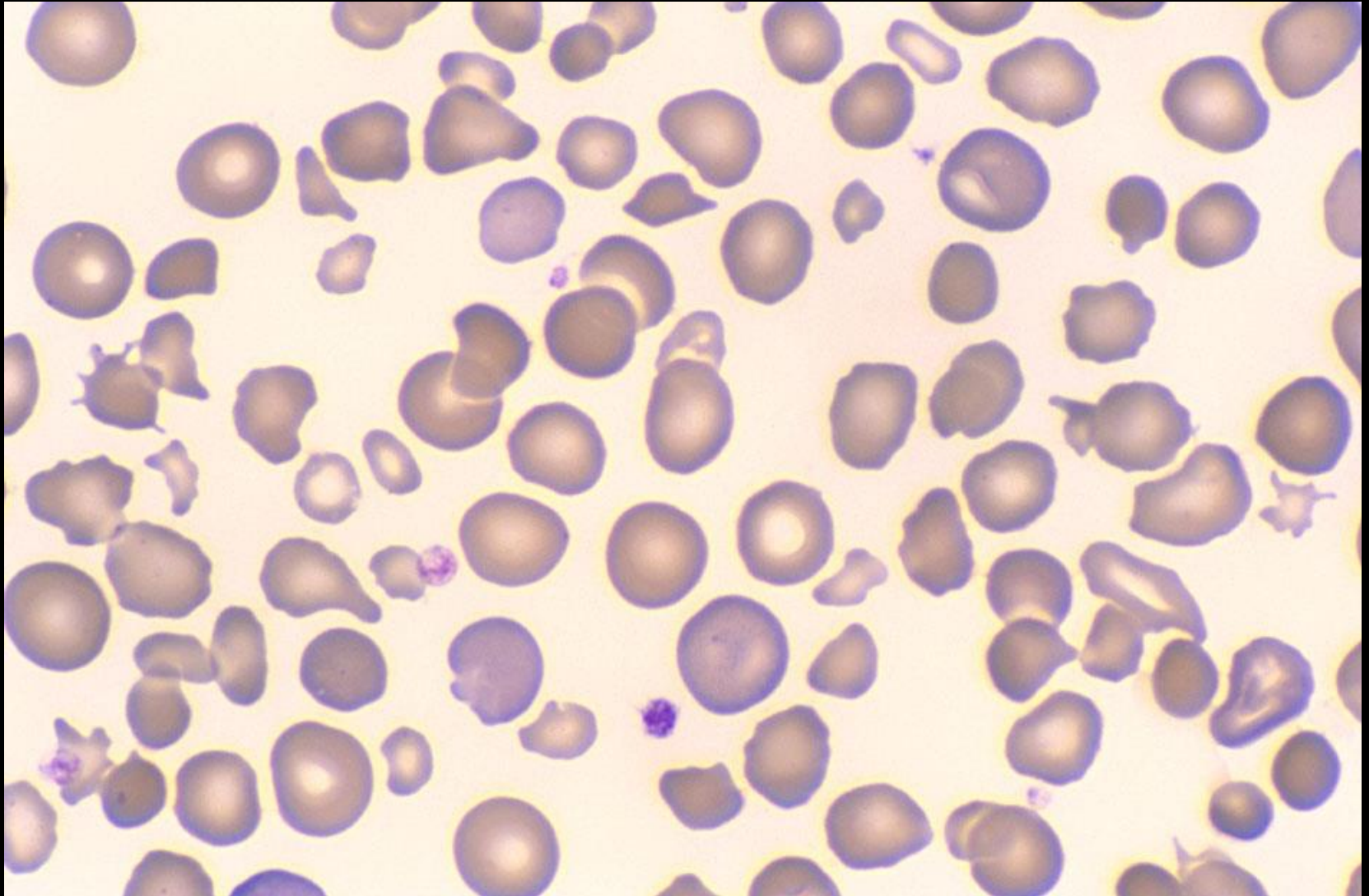
- Rh haemolytic disease of the newborn

CASE STUDY

One day old neonate: Anaemia/high bilirubin

• Hb	113	(121-191)	g/L
• RBC	4.02	(3.34-5.40)	$\times 10^{12}/L$
• MCV	84.6	(101-117)	fL
• MCH	28.1	(33.0-38.0)	pg
• MCHC	332	(302-341)	g/L
• RDW-CV	19.2	(15.5-19.2)	%
• WBC	21.3	(9.6-30.4)	$\times 10^9/L$
• Plats	203	(195-434)	$\times 10^9/L$

Case study (13)



CASE STUDY

Blood film comments:

Marked anisocytosis

Moderate microcytes

Slight round macrocytes

Moderate polychromasia

Slight spherocytes

Marked fragments

CASE STUDY

Chemistry results:

Bilirubin total	375 umol/L	0-85
Bilirubin conjugated	249 umol/L	<10

CASE STUDY

DIAGNOSIS:

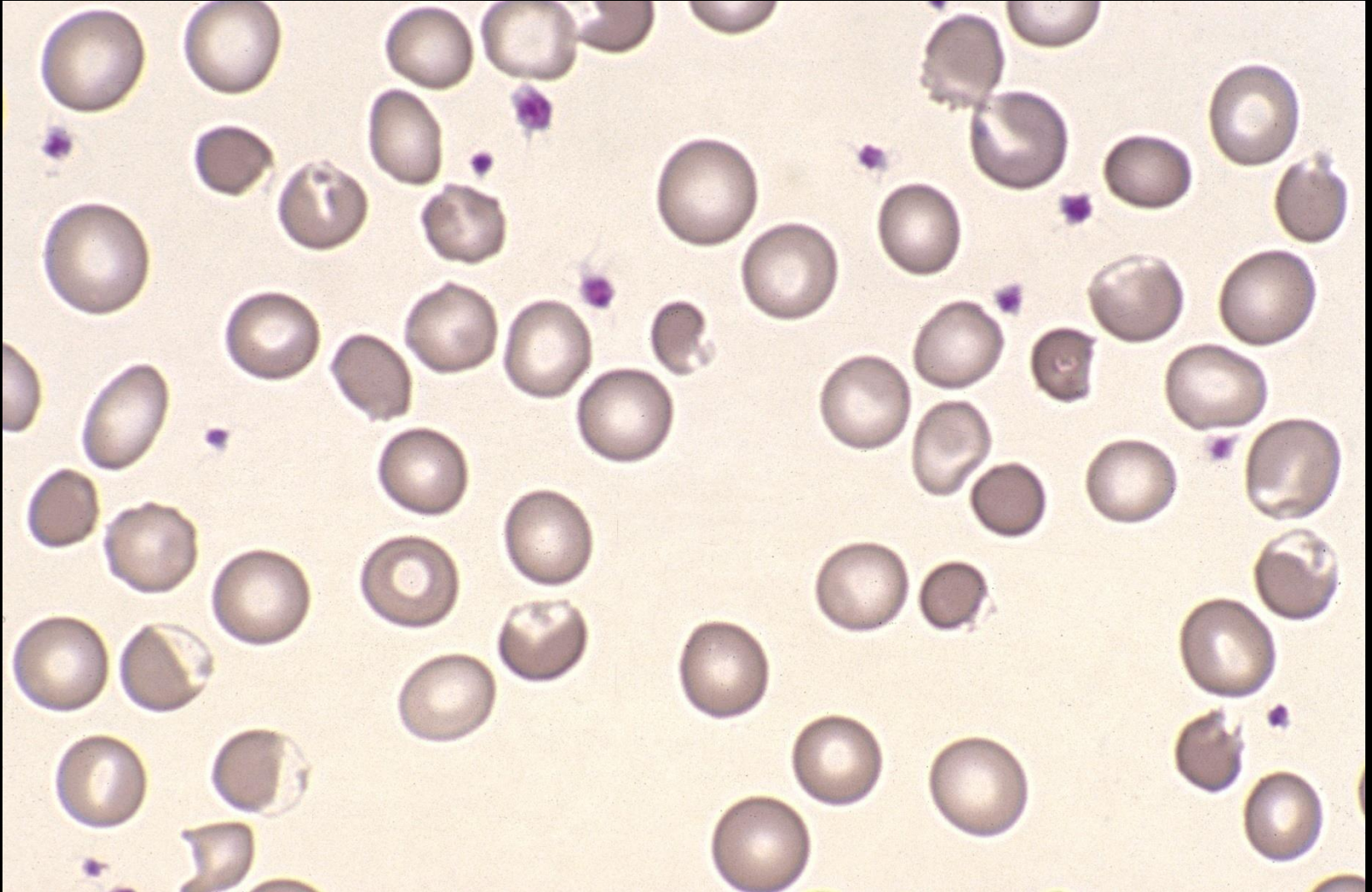
- Hereditary pyropoikilocytosis (HPP)

CASE STUDY

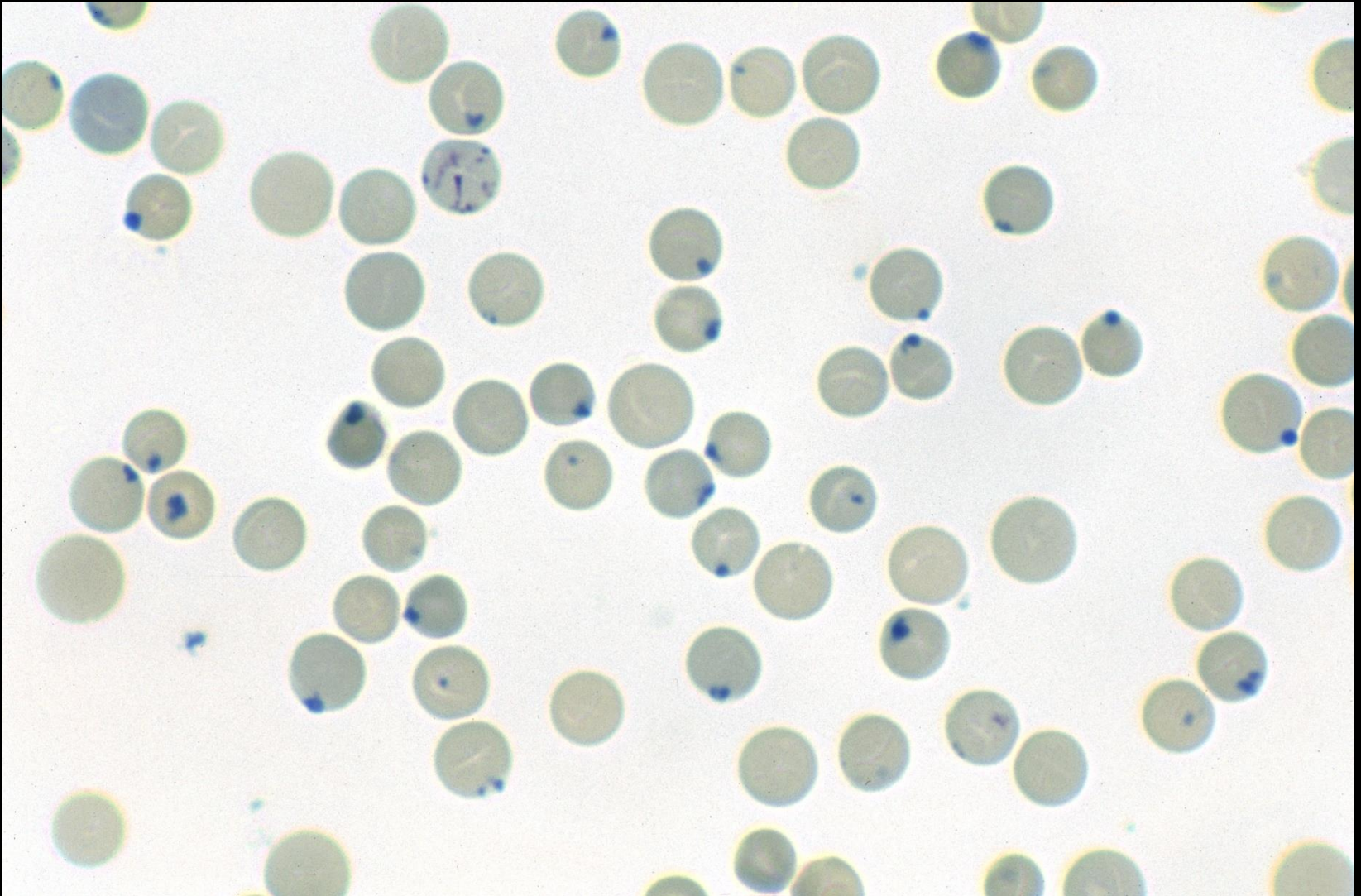
Two weeks old neonate: Return to hospital with unexpected anaemia

• Hb	94	(125-205)	g/L
• RBC	2.77	(3.60-5.50)	$\times 10^{12}/L$
• MCV	102.5	(84-110)	fL
• MCH	33.9	(29.0-38.0)	pg
• MCHC	331	(320-353)	g/L
• RDW-CV	18.2	(12.0-18.0)	%
• WBC	19.8	(6.8-20.0)	$\times 10^9/L$
• Plats	399	(250-600)	$\times 10^9/L$

Case study (14)



Case study (14)



CASE STUDY

Blood film comments:

Moderate anisocytosis

Slight round macrocytes

Slight polychromasia

Moderate bite and blister cells

? Exposure to an oxidant

G6PD screen: Normal activity

CASE STUDY

DIAGNOSIS:

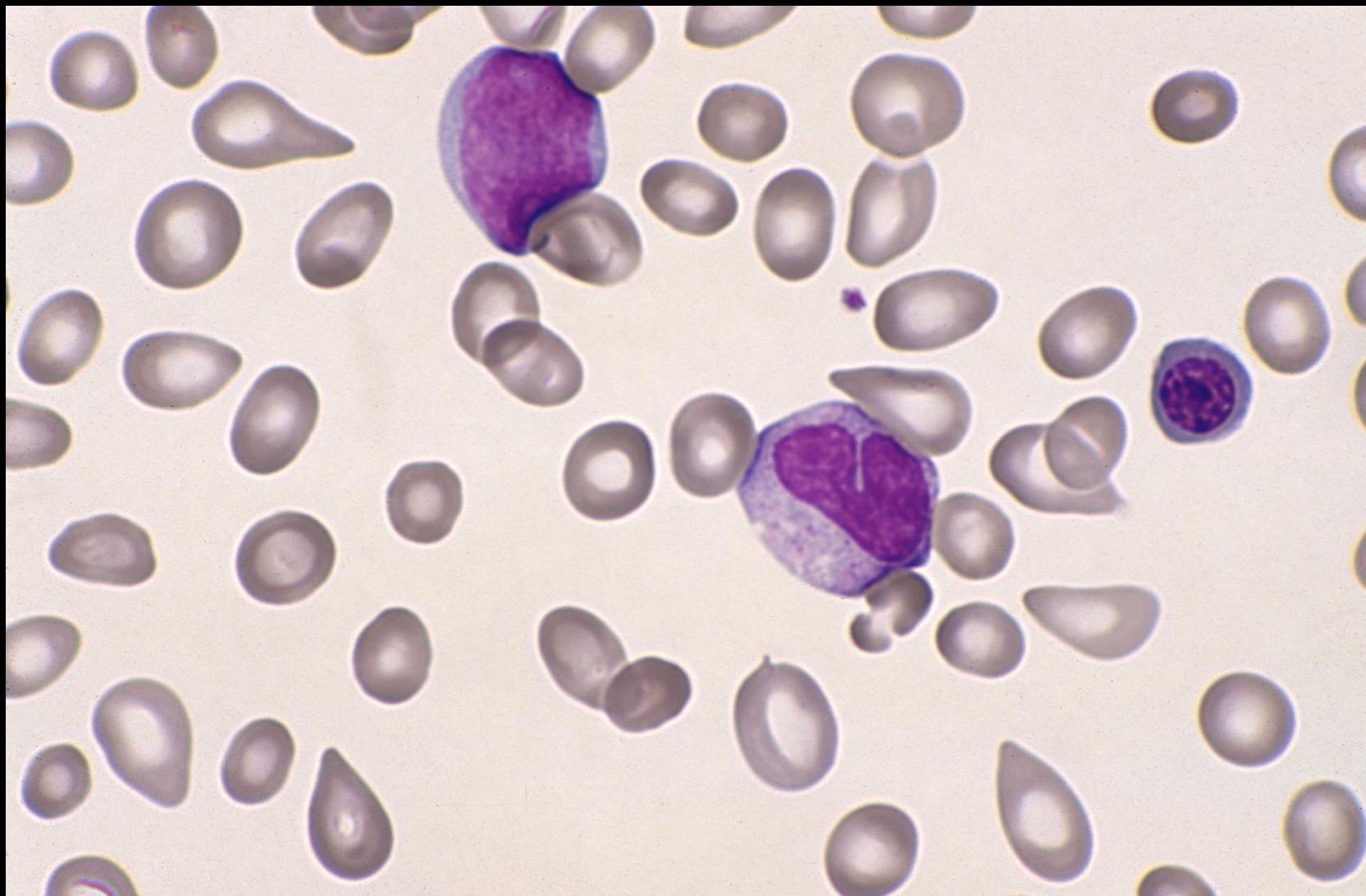
- Oxidant haemolysis (naphthalene-induced)

CASE STUDY

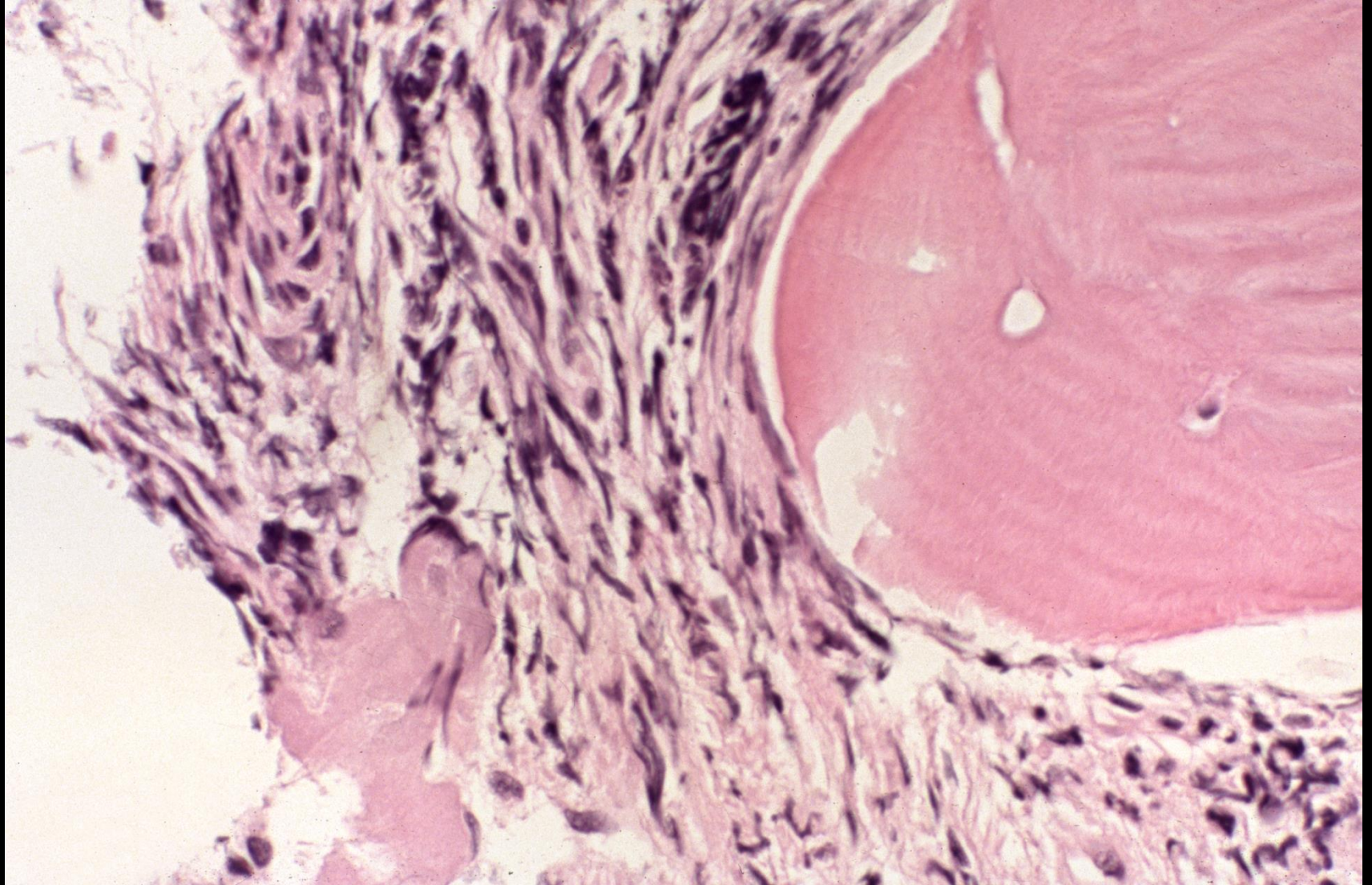
Male 60 years: Splenomegaly FI

• Hb	127	(130-180)	g/L
• RBC	4.01	(4.50-6.50)	$\times 10^{12}/L$
• MCV	90.3	(80-100)	fL
• MCH	31.7	(26.5-33.0)	pg
• MCHC	319	(310-360)	g/L
• RDW-CV	16.2	(12.0-14.5)	%
• WBC	8.1	(3.50-11.00)	$\times 10^9/L$
• Plats	100	(150-500)	$\times 10^9/L$

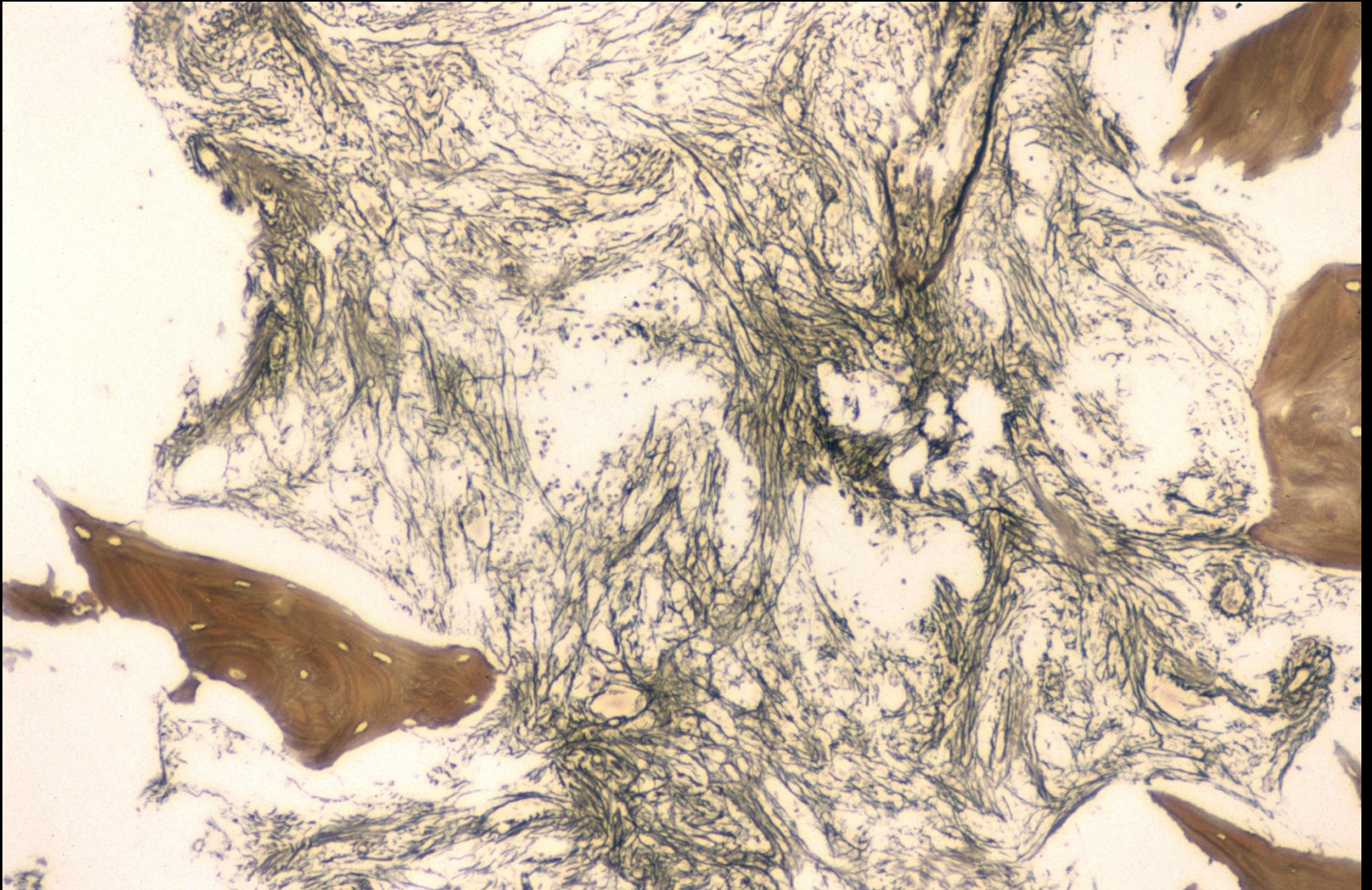
Case Study (15)



Case study (15)



Case study (15)



CASE STUDY

Blood film comments:

Slight anisocytosis

Slight polychromasia

Moderate tear drop poikilocytes

Large and giant platelets

Leucoerythroblastic blood picture

CASE STUDY

DIAGNOSIS:

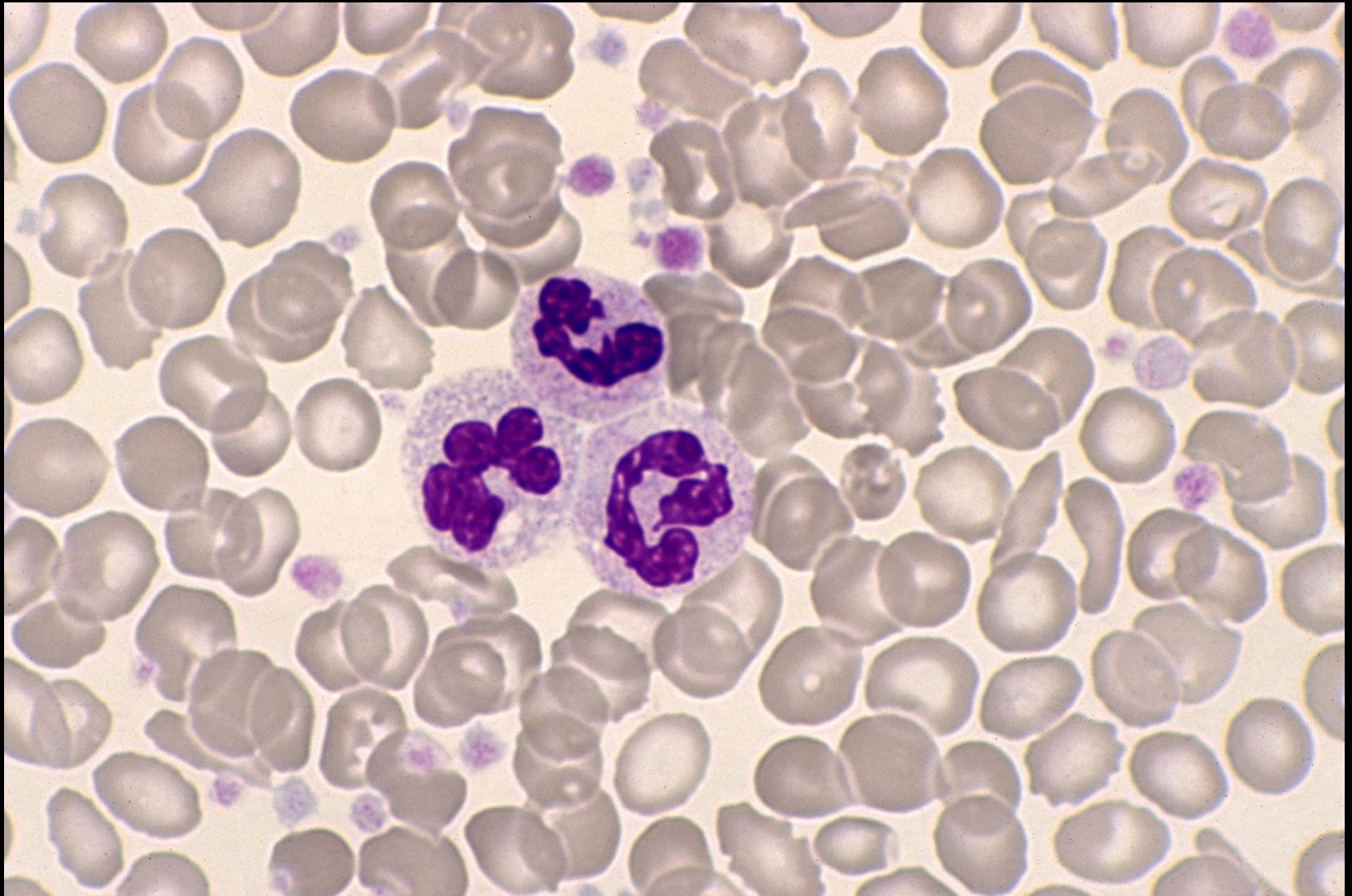
- Primary myelofibrosis
- JAK2V617F Positive

CASE STUDY

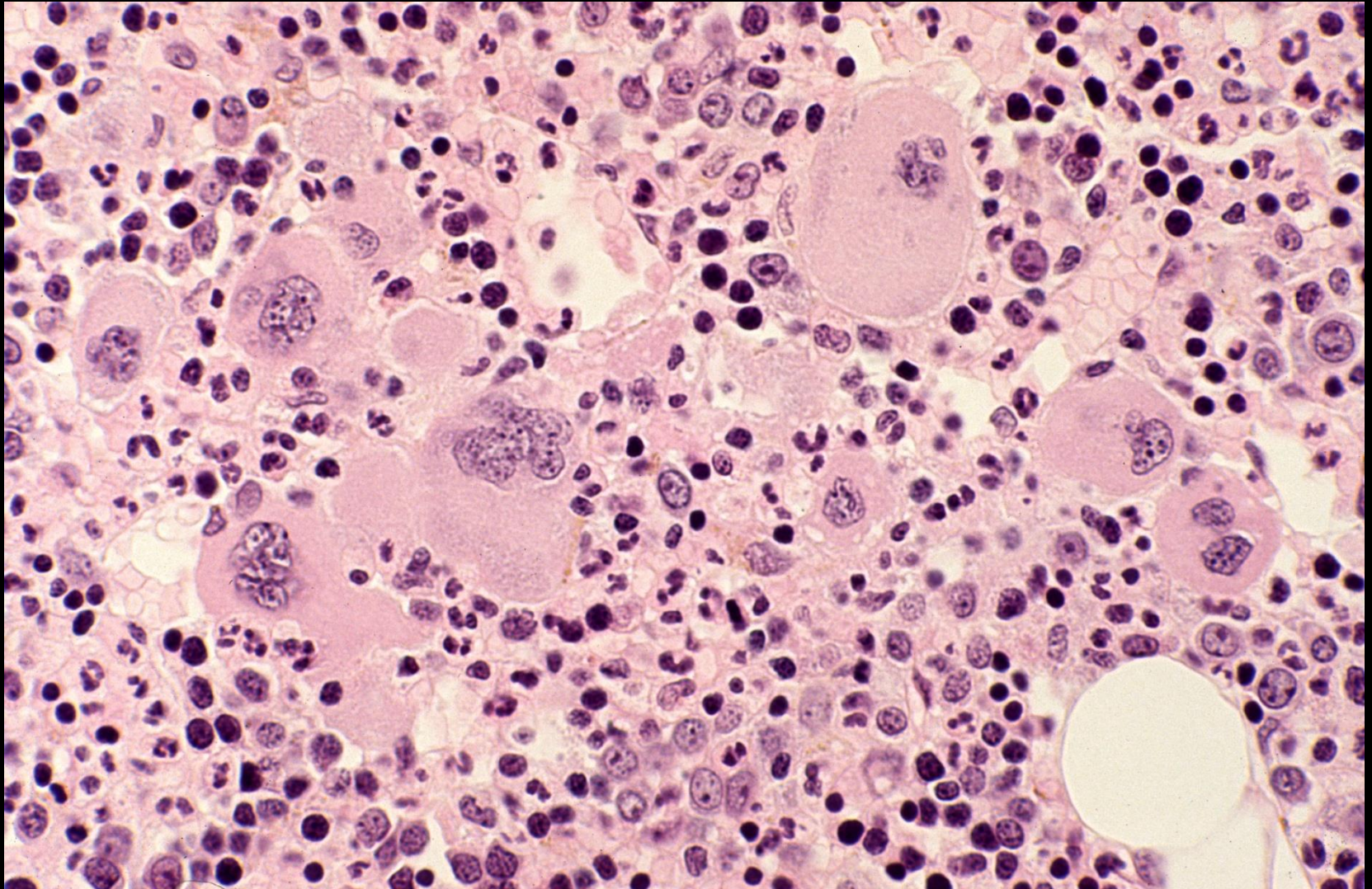
Male 55 years: Hi Hb for investigation

• Hb	189	(130-180)	g/L
• RBC	7.46	(4.50-6.50)	$\times 10^{12}/L$
• MCV	80.4	(80-100)	fL
• MCH	25.3	(26.5-33.0)	pg
• MCHC	315	(310-360)	g/L
• RDW-CV	16.2	(12.0-14.5)	%
• WBC	15.1	(3.50-11.00)	$\times 10^9/L$
• Plats	428	(150-400)	$\times 10^9/L$

Case study (16)



Case study (16)



CASE STUDY

Blood film comments:

Slight anisocytosis

Slight microcytes

Slight hypochromasia

Large and giant platelets

CASE STUDY

DIAGNOSIS:

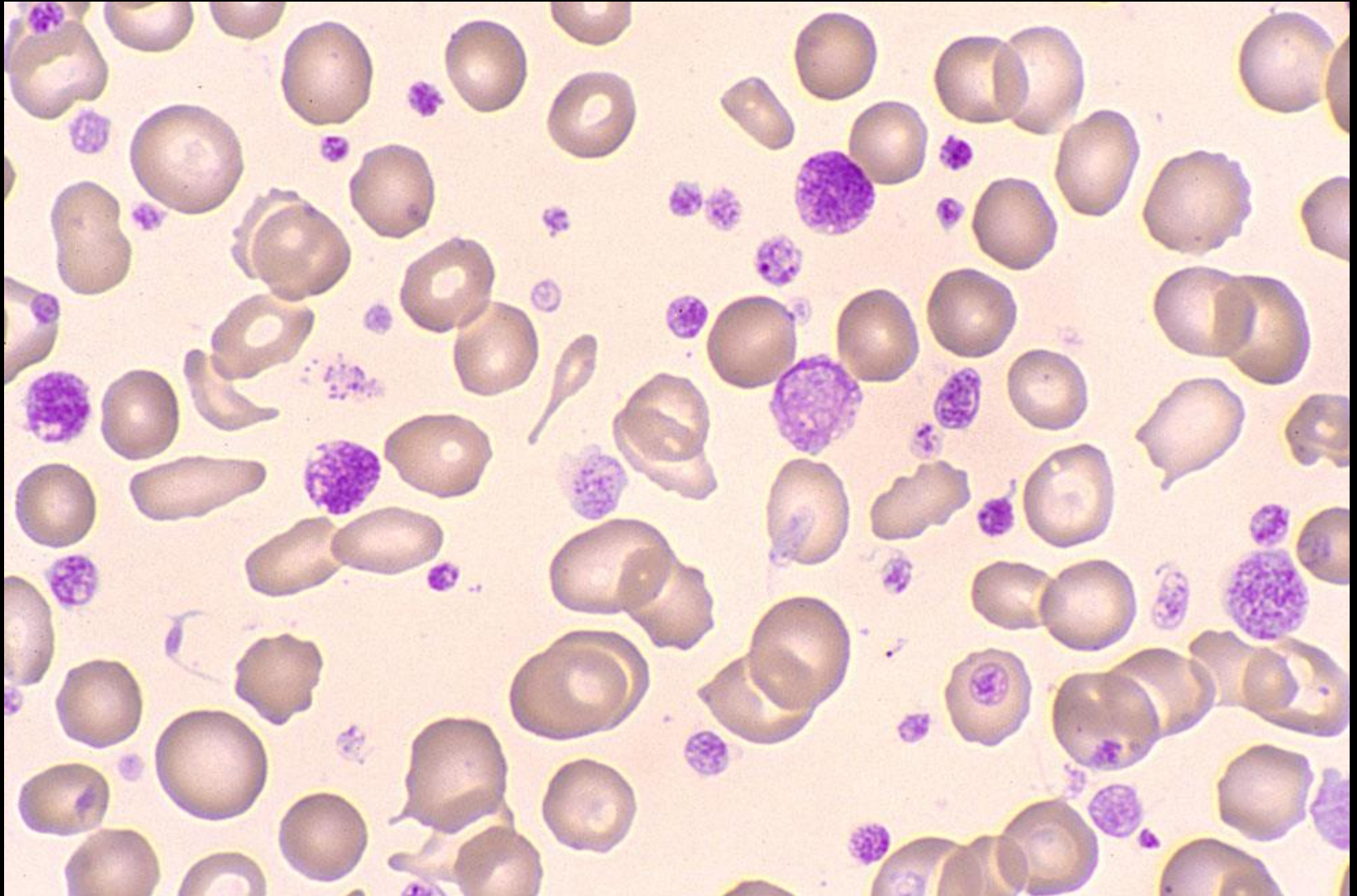
- Polycythaemia vera
- JAK2V617F positive

CASE STUDY

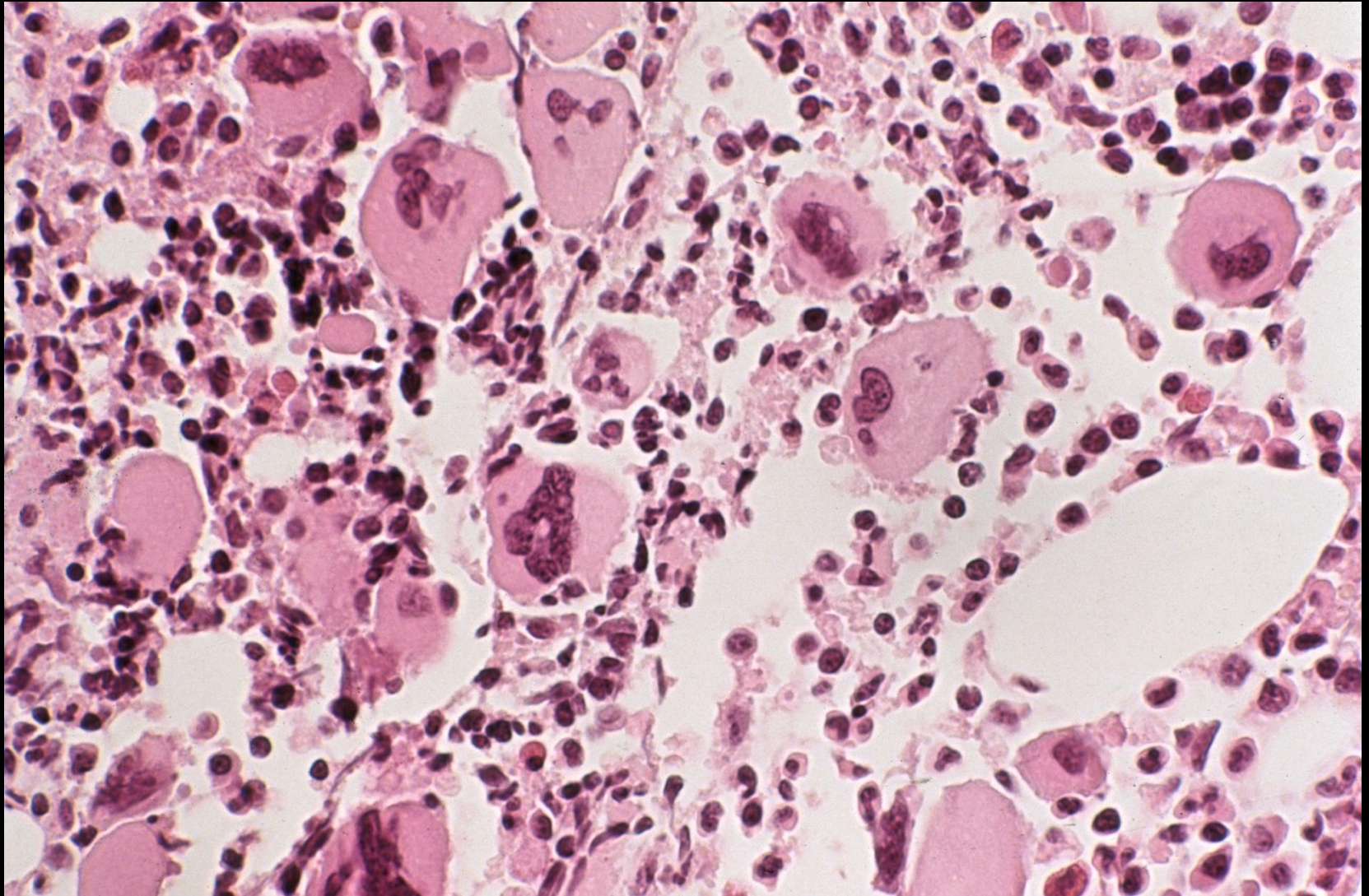
Male 58 years: For routine FBC

• Hb	110	(130-180)	g/L
• RBC	4.47	(4.50-6.50)	$\times 10^{12}/L$
• MCV	79.6	(80-100)	fL
• MCH	24.6	(26.5-33.0)	pg
• MCHC	309	(310-360)	g/L
• RDW-CV	23.1	(12.0-14.5)	%
• WBC	13.8	(3.50-11.00)	$\times 10^9/L$
• Plats	908	(150-400)	$\times 10^9/L$

Case study (17)



Case study (17)



CASE STUDY

Blood film comments:

Slight anisocytosis

Slight microcytes

Slight hypochromasia

Large and giant platelets

CASE STUDY

DIAGNOSIS:

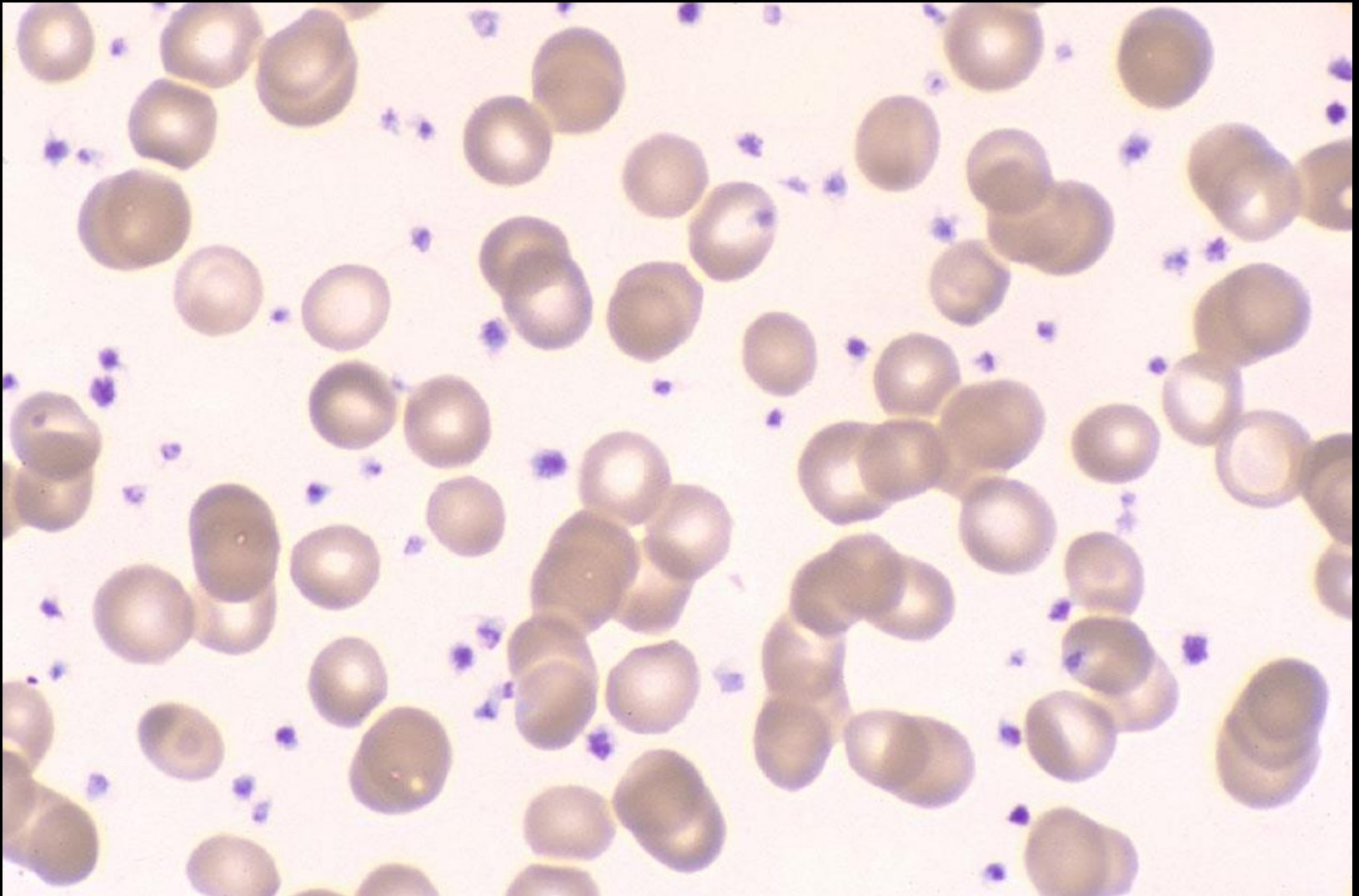
- Essential thrombocythaemia
- JAK2V617F Positive

CASE STUDY

Male 6 years: Juvenile rheumatoid arthritis

• Hb	76	(110-139)	g/L
• RBC	2.79	(3.96-4.92)	$\times 10^{12}/L$
• MCV	87.1	(74-86)	fL
• MCH	27.2	(25.5-30.6)	pg
• MCHC	313	(332-360)	g/L
• RDW-CV	15.2	(11.9-14.9)	%
• WBC	15.7	(4.7-12.3)	$\times 10^9/L$
• Plats	1087	(205-457)	$\times 10^9/L$
• ESR	89	mms/hr	

Case study (18)



CASE STUDY

Blood film comments:

Slight anisocytosis

Marked rouleaux

Thrombocytosis

CASE STUDY

DIAGNOSIS:

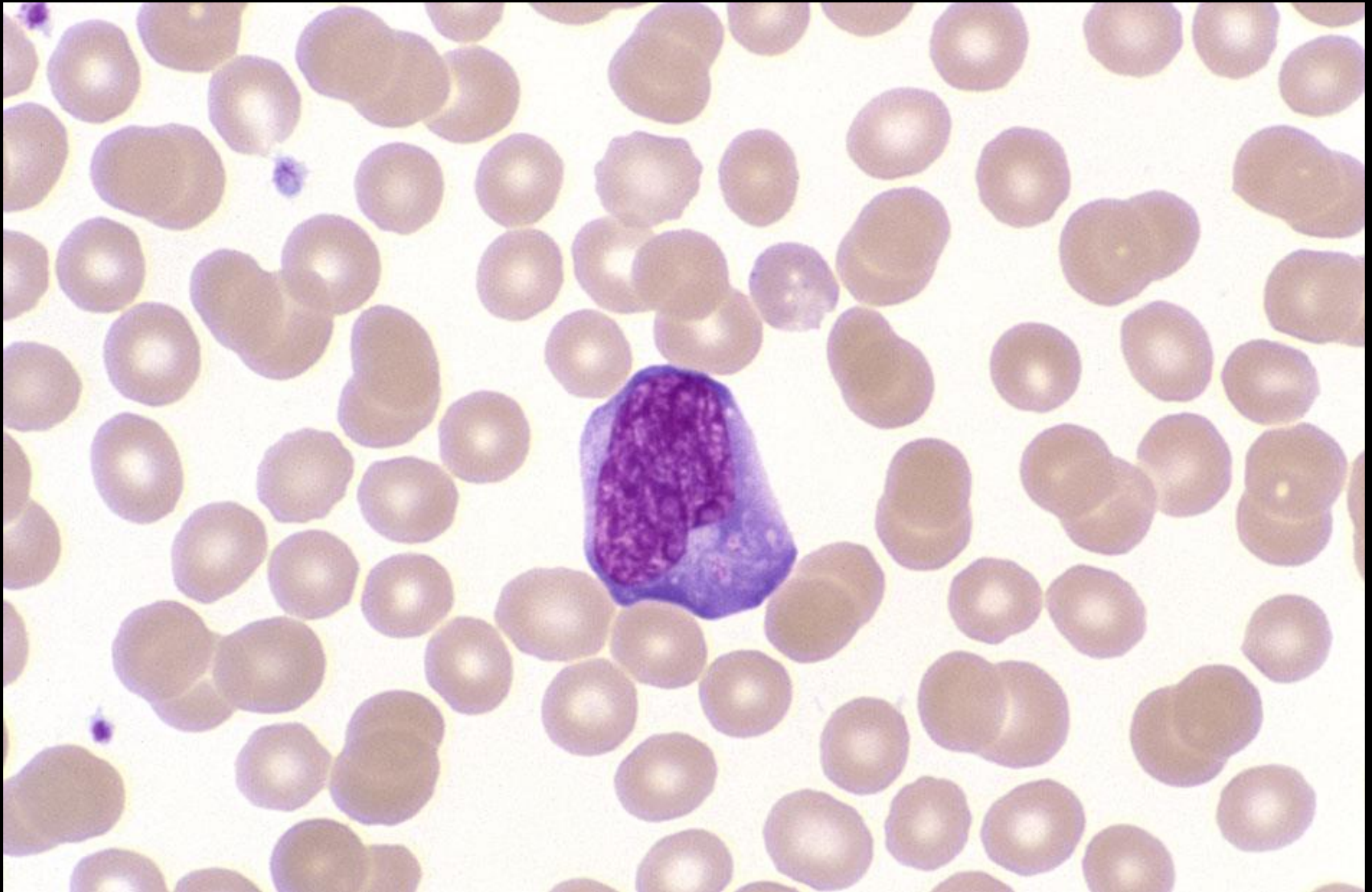- Reactive thrombocytosis

CASE STUDY

Female 9 years: Fever/lymphadenopathy

• Hb	122	(113-143)	g/L
• RBC	4.72	(3.98-5.15)	$\times 10^{12}/L$
• MCV	79.0	(75-86)	fL
• MCH	25.8	(25.7-30.6)	pg
• MCHC	327	(335-361)	g/L
• RDW-CV	14.3	(12.0-14.1)	%
• WBC	15.9	(4.7-12.2)	$\times 10^9/L$
• Plats	217	(187-415)	$\times 10^9/L$

Case study (19)



CASE STUDY

Blood film comments:

Reactive lymphocytes present

Red cells normal for age

Monospot (Clearview IM II) test: Positive

CASE STUDY

DIAGNOSIS:

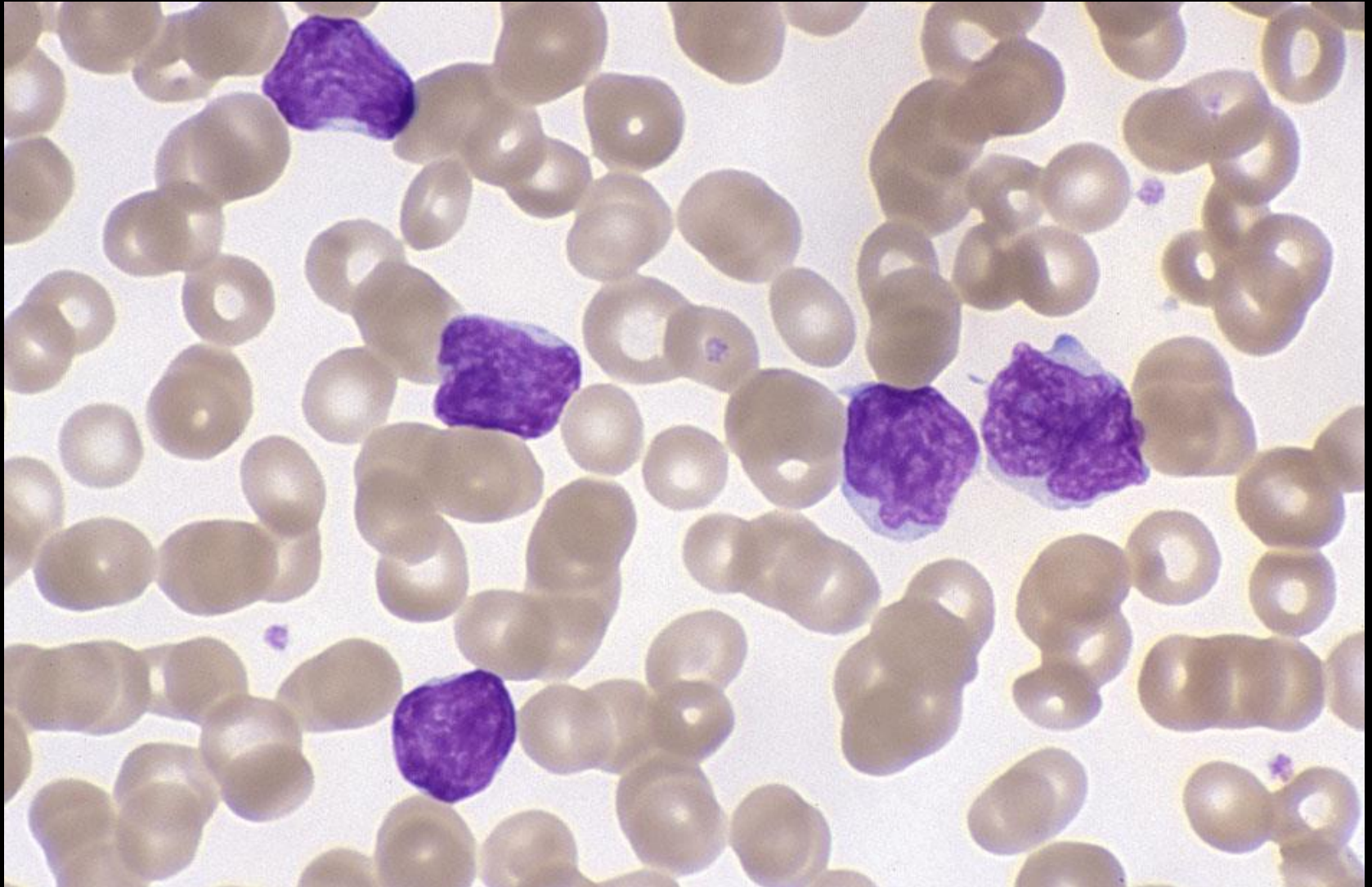
- Infectious mononucleosis

CASE STUDY

Male 53 years: Lymphadenopathy/splenomegaly FI

• Hb	72	(130-180)	g/L
• RBC	2.54	(4.50-6.50)	$\times 10^{12}/L$
• MCV	93.7	(80-100)	fL
• MCH	28.3	(26.5-33.0)	pg
• MCHC	327	(310-360)	g/L
• RDW-CV	14.3	(12.0-14.5)	%
• WBC	61.1	(3.50-11.00)	$\times 10^9/L$
• Plats	10	(150-400)	$\times 10^9/L$

Case study (20)



CASE STUDY

Blood film comments:

Slight anisocytosis

Slight rouleaux

82% lymphoma cells present

CASE STUDY

Immunophenotype:

- SIg⁺, CD5⁻, CD10⁺, CD19⁺, CD20⁺, CD22⁺, CD23⁺, BCL2⁺

Cytogenetics:

- t(14;18)(q32;q21)

CASE STUDY

DIAGNOSIS:

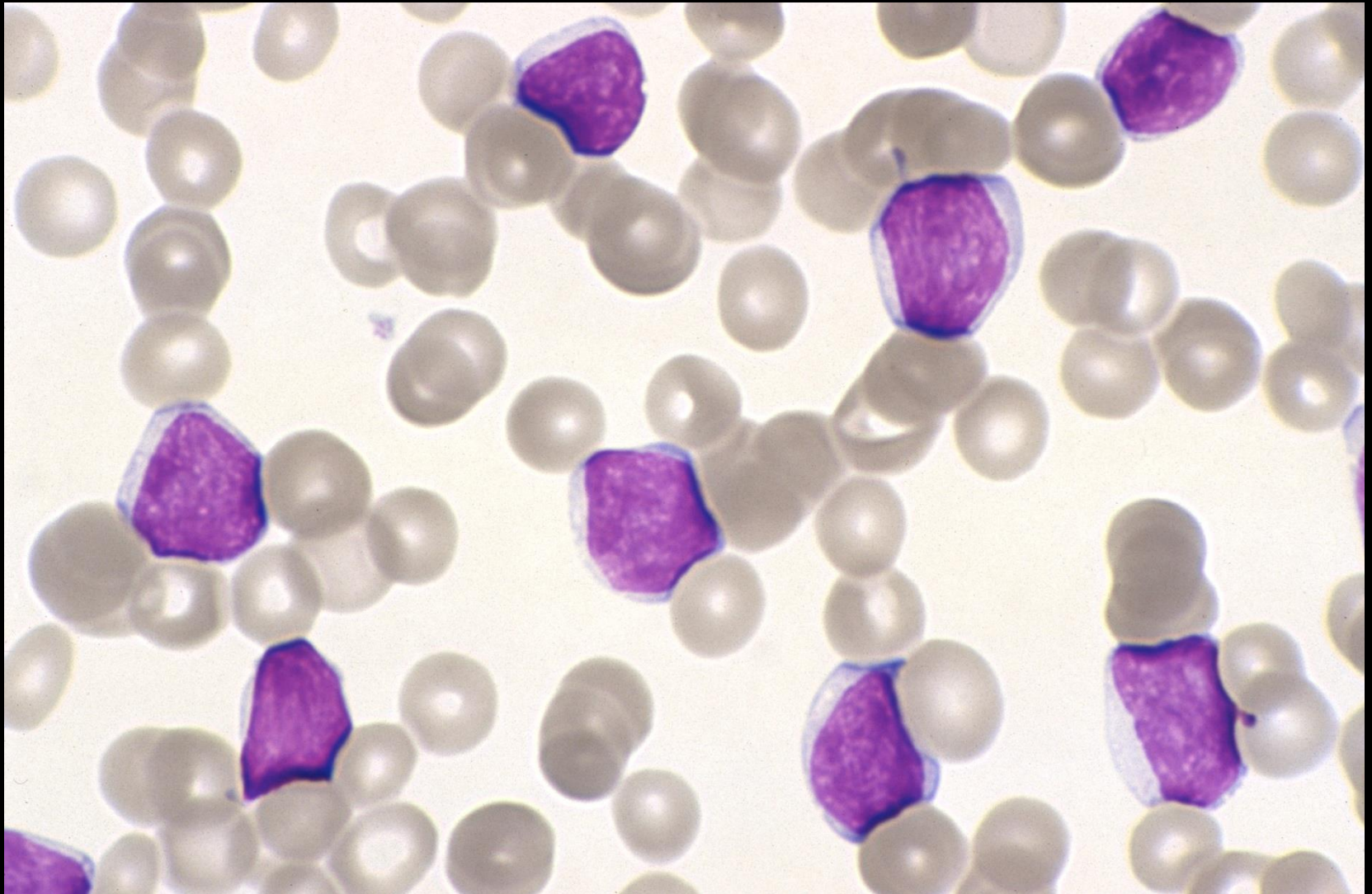
- Follicular non-Hodgkin lymphoma with bone marrow involvement

CASE STUDY

Male 74 years: Routine FBC

• Hb	130	(130-180)	g/L
• RBC	4.14	(4.50-6.50)	$\times 10^{12}/L$
• MCV	93.2	(80-100)	fL
• MCH	28.0	(26.5-33.0)	pg
• MCHC	337	(310-360)	g/L
• RDW-CV	14.7	(12.0-14.5)	%
• WBC	93.8	(3.50-11.00)	$\times 10^9/L$
• Plats	60	(150-400)	$\times 10^9/L$

Case study (21)



CASE STUDY

Blood film comments:

Slight anisocytosis

100% lymphocytes

Absolute count $93.8 \times 10^9/L$

CASE STUDY

Immunophenotype:

- SIg⁺ (weak), CD5⁺, CD10⁻, CD19⁺, CD20⁺ (weak), CD22⁺ (weak), CD23⁺

Cytogenetics:

- add(14)(q32) identified by FISH

CASE STUDY

DIAGNOSIS:

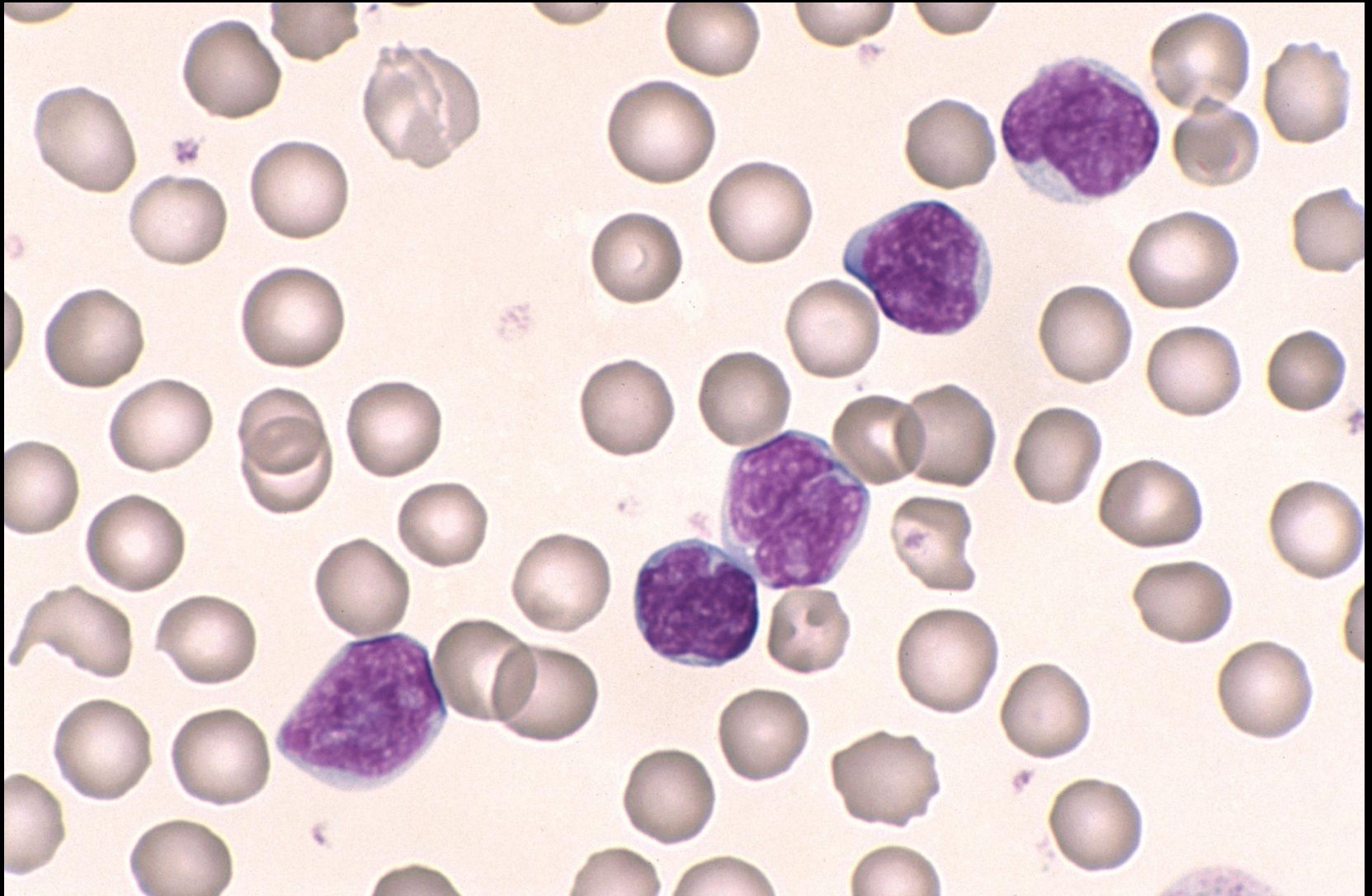
- B-Cell chronic lymphocytic leukaemia/small lymphocytic lymphoma (CLL/SLL)

CASE STUDY

Male 4 weeks: Bronchiolitis

• Hb	102	(102-130)	g/L
• RBC	3.37	(3.38-3.94)	$\times 10^{12}/L$
• MCV	87.8	(84-98)	fL
• MCH	30.3	(29.0-33.8)	pg
• MCHC	345	(333-355)	g/L
• RDW-CV	13.7	(12.6-16.0)	%
• WBC	16.2	(6.4-12.1)	$\times 10^9/L$
• Plats	643	(270-645)	$\times 10^9/L$

Case study (22)



CASE STUDY

Blood film comments:

Slight anisocytosis

Many of the lymphocytes have cleaved nuclei

A feature seen in *Bordetella pertussis*

76% lymphocytes

Absolute count $12.4 \times 10^9/L$

CASE STUDY

DIAGNOSIS:

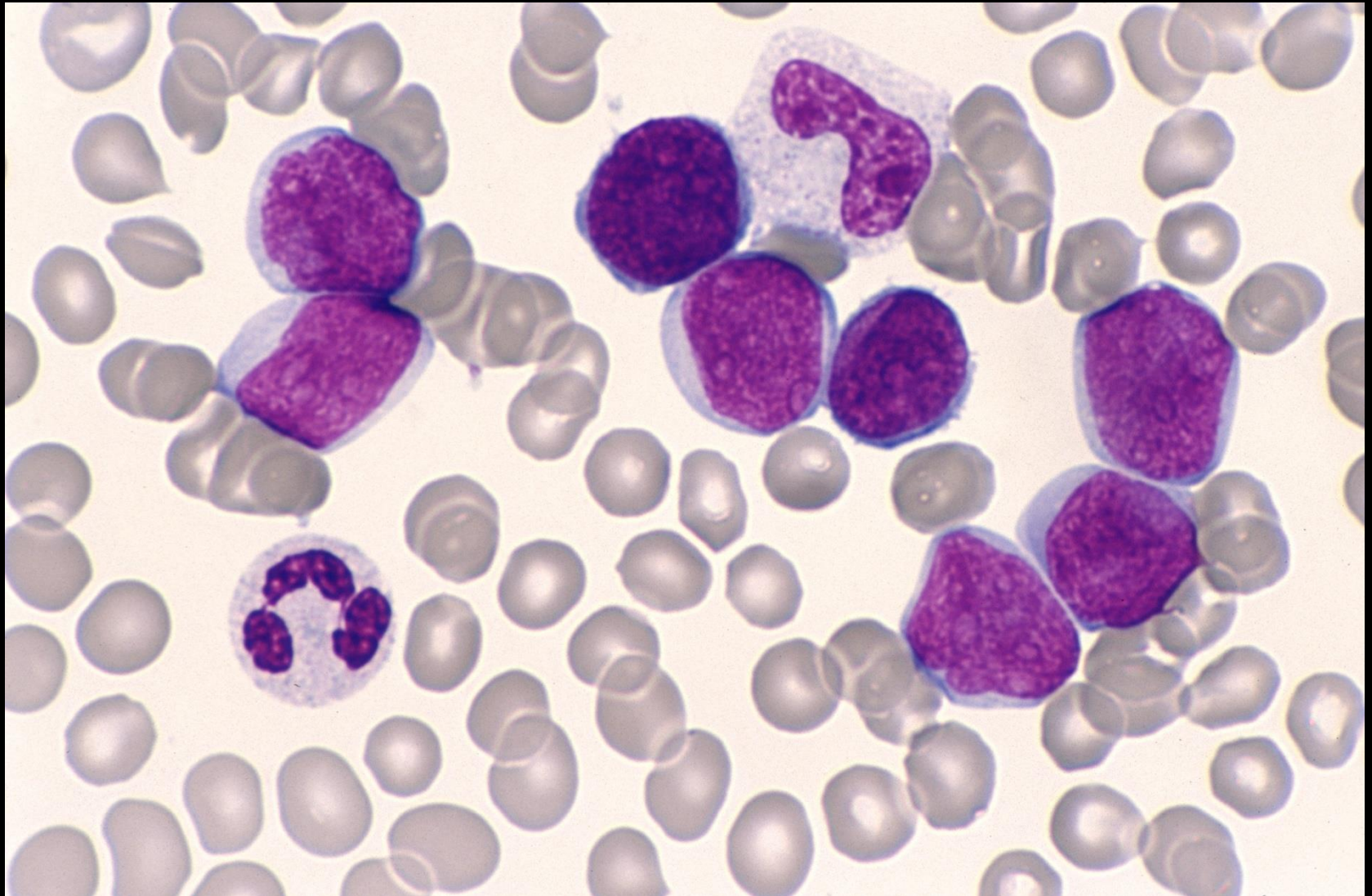
- *Bordetella pertussis* infection

CASE STUDY

Male 4 years: Pale with petechial rash

• Hb	73	(107-136)	g/L
• RBC	2.61	(3.86-5.01)	$\times 10^{12}/L$
• MCV	78.5	(73-85)	fL
• MCH	28.0	(24.8-29.9)	((pg
• MCHC	356	(329-359)	g/L
• RDW-CV	12.6	(12.1-15.6)	%
• WBC	25.0	(4.9-12.8)	$\times 10^9/L$
• Plats	78	(214-483)	$\times 10^9/L$

Case study (23)



CASE STUDY

Blood film comments:

Red cells normal for age

82% blast cells

CASE STUDY

Immunophenotype:

- TdT⁺, HLA-DR⁺, SIg⁻, cyt-μ⁻, CD10⁺, CD19⁺, CD22⁺, CD34⁺

Cytogenetics:

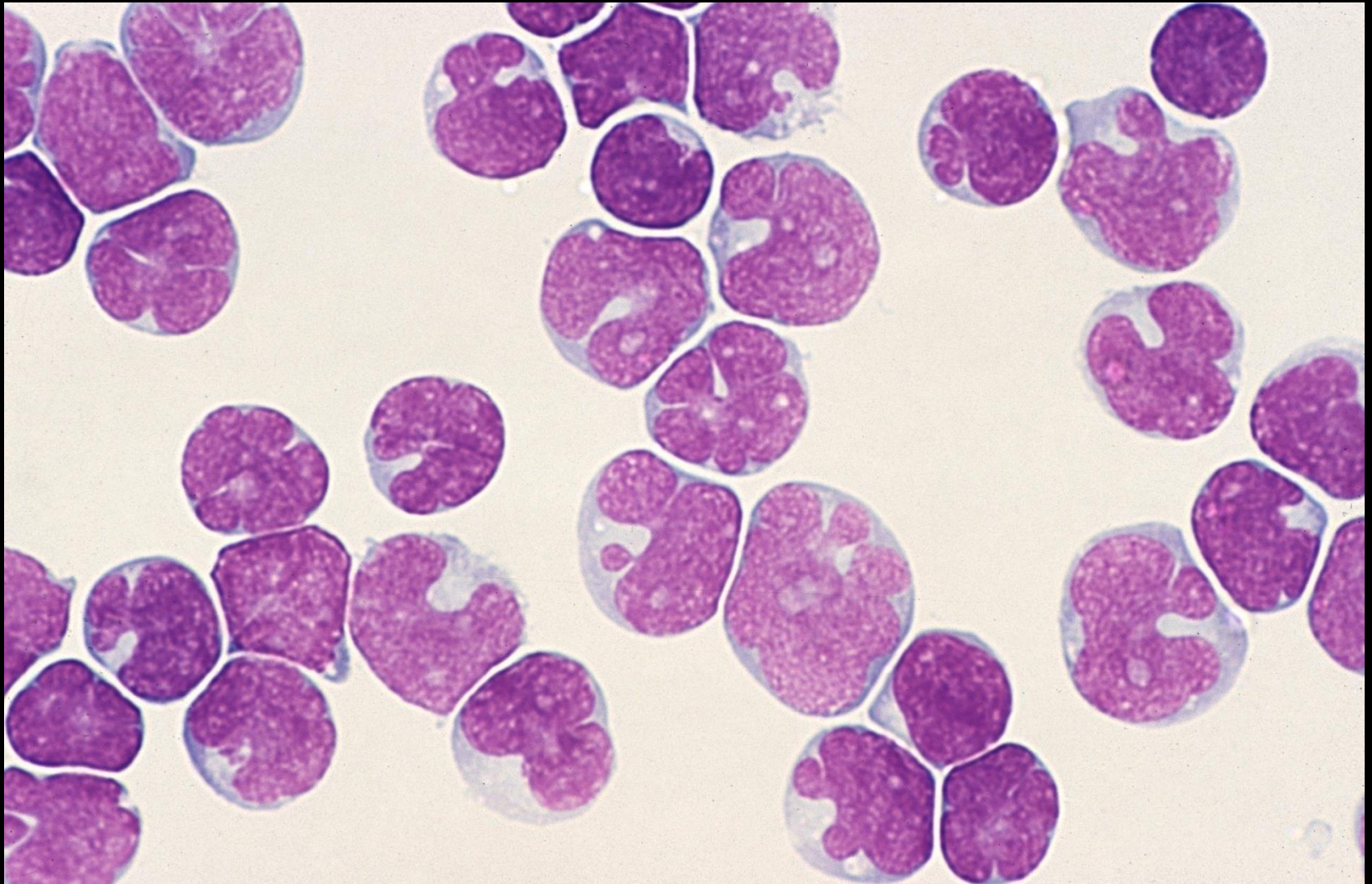
- t(12;21)(p13;q22)

CASE STUDY

DIAGNOSIS:

- Precursor B-Cell Acute Lymphoblastic Leukaemia

T-Cell ALL CNS relapse

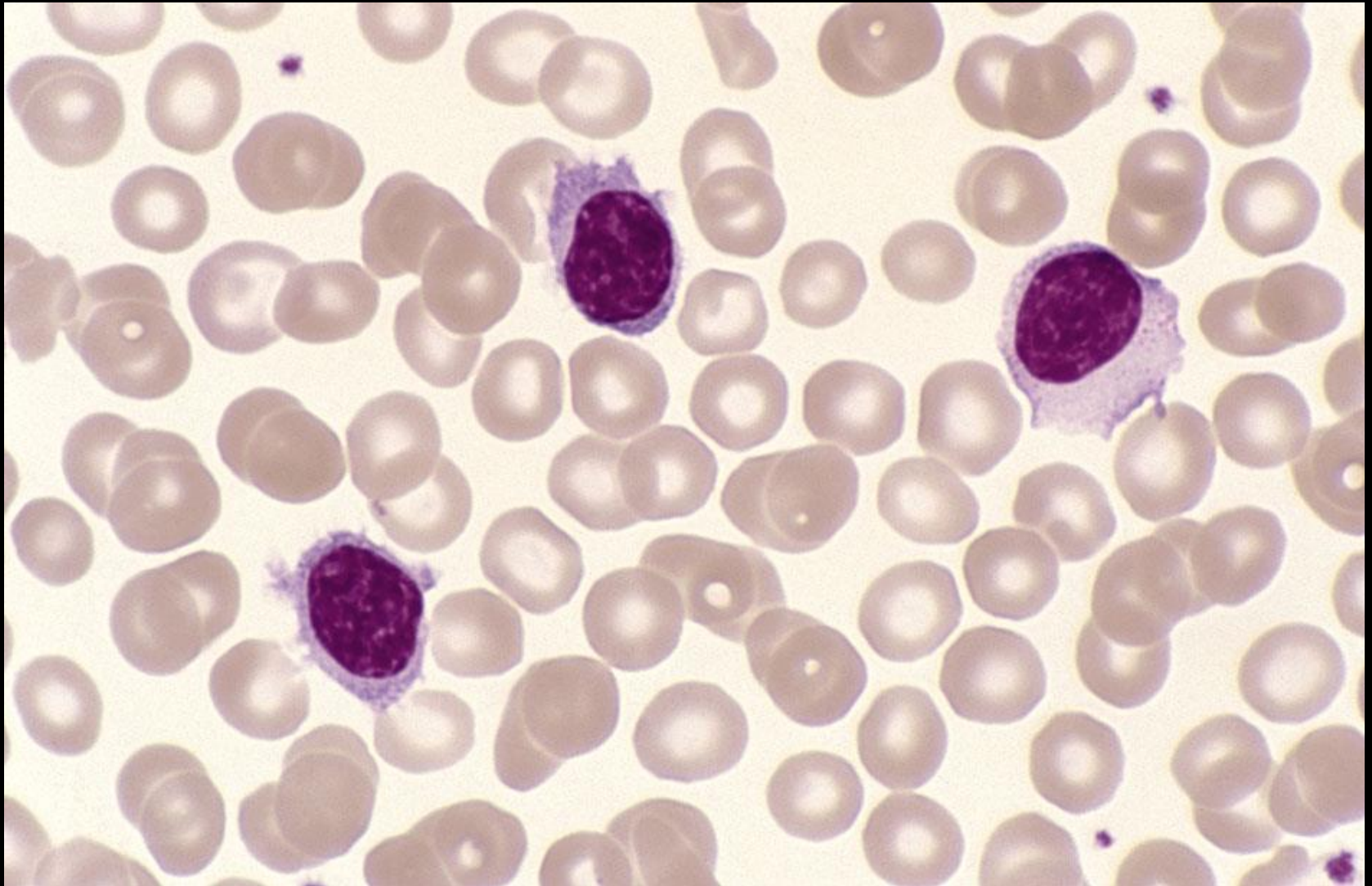


CASE STUDY

Male 74 years: Splenomegaly FI

• Hb	114	(130-180)	g/L
• RBC	4.48	(4.50-6.50)	$\times 10^{12}/L$
• MCV	83.5	(80-100)	fL
• MCH	25.4	(26.5-33.0)	pg
• MCHC	305	(310-360)	g/L
• RDW-CV	12.6	(12.0-14.5)	%
• WBC	13.5	(3.50-11.00)	$\times 10^9/L$
• Plats	258	(150-400)	$\times 10^9/L$

Case study (24)



CASE STUDY

Blood film comments:

Slight microcytes

Slight hypochromasia

Absolute lymphocytosis $5.1 \times 10^9/L$

23% villous lymphocytes present

CASE STUDY

Immunophenotype:

- SIg⁺, CD5⁻, CD10⁻, CD19⁺, CD20⁺, CD22⁺, CD23⁻

Cytogenetics:

- del(7q)

CASE STUDY

DIAGNOSIS:

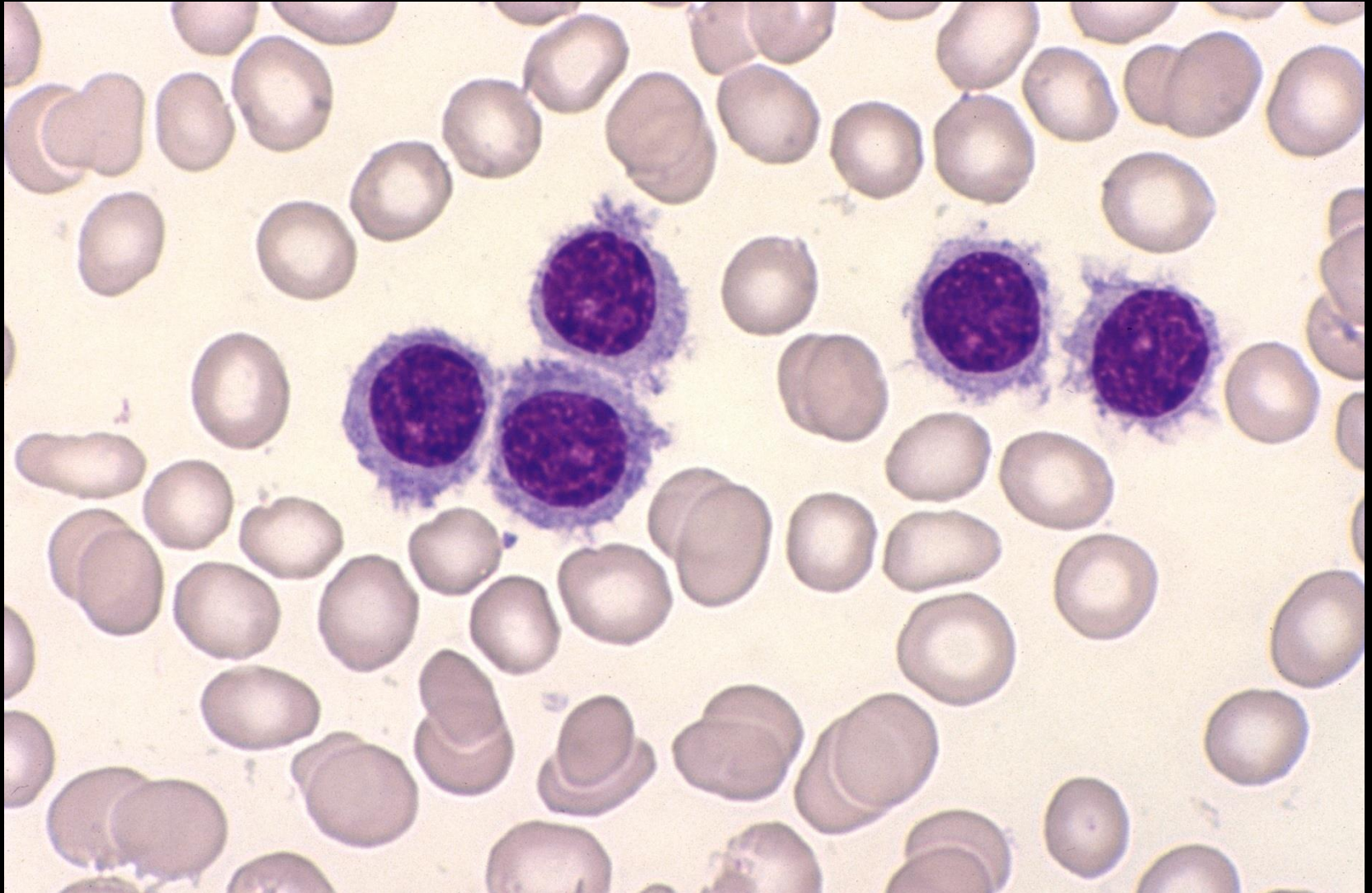
- Splenic Marginal Zone Lymphoma (SMZL)

CASE STUDY

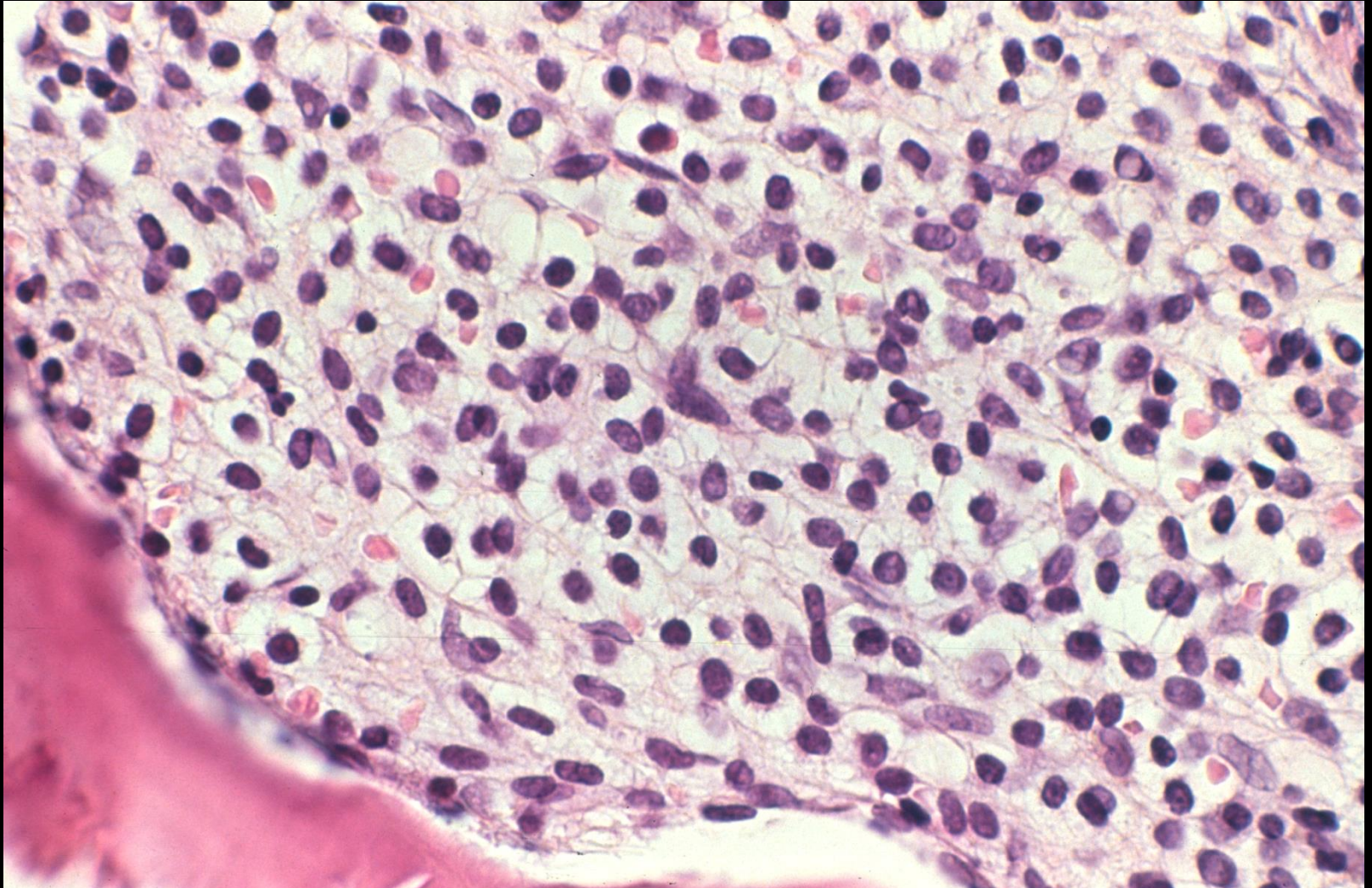
Female 58 years: Fatigue/splenomegaly

• Hb	127	(115-165)	g/L
• RBC	4.13	(3.80-5.80)	$\times 10^{12}/L$
• MCV	93.9	(80-100)	fL
• MCH	30.8	(26.5-33.0)	pg
• MCHC	327	(310-360)	g/L
• RDW-CV	12.6	(12.0-14.5)	%
• WBC	85.2	(3.50-11.00)	$\times 10^9/L$
• Plats	127	(150-400)	$\times 10^9/L$

Case study (25)



Case study (25)



CASE STUDY

Blood film comments:

Red cells normal

Slight thrombocytopenia

Absolute lymphocytosis $81.0 \times 10^9/L$

Majority of lymphocytes have villous-like projections around the entire circumference with a centrally placed nucleus

CASE STUDY

Immunophenotype:

- SIg⁺, CD5⁻, CD10⁻, CD11c⁺ (strong), CD19⁺, CD20⁺, CD22⁺, CD23⁻, CD25⁻, CD103⁺

Cytogenetics:

- add(14)(q32)

CASE STUDY

DIAGNOSIS:

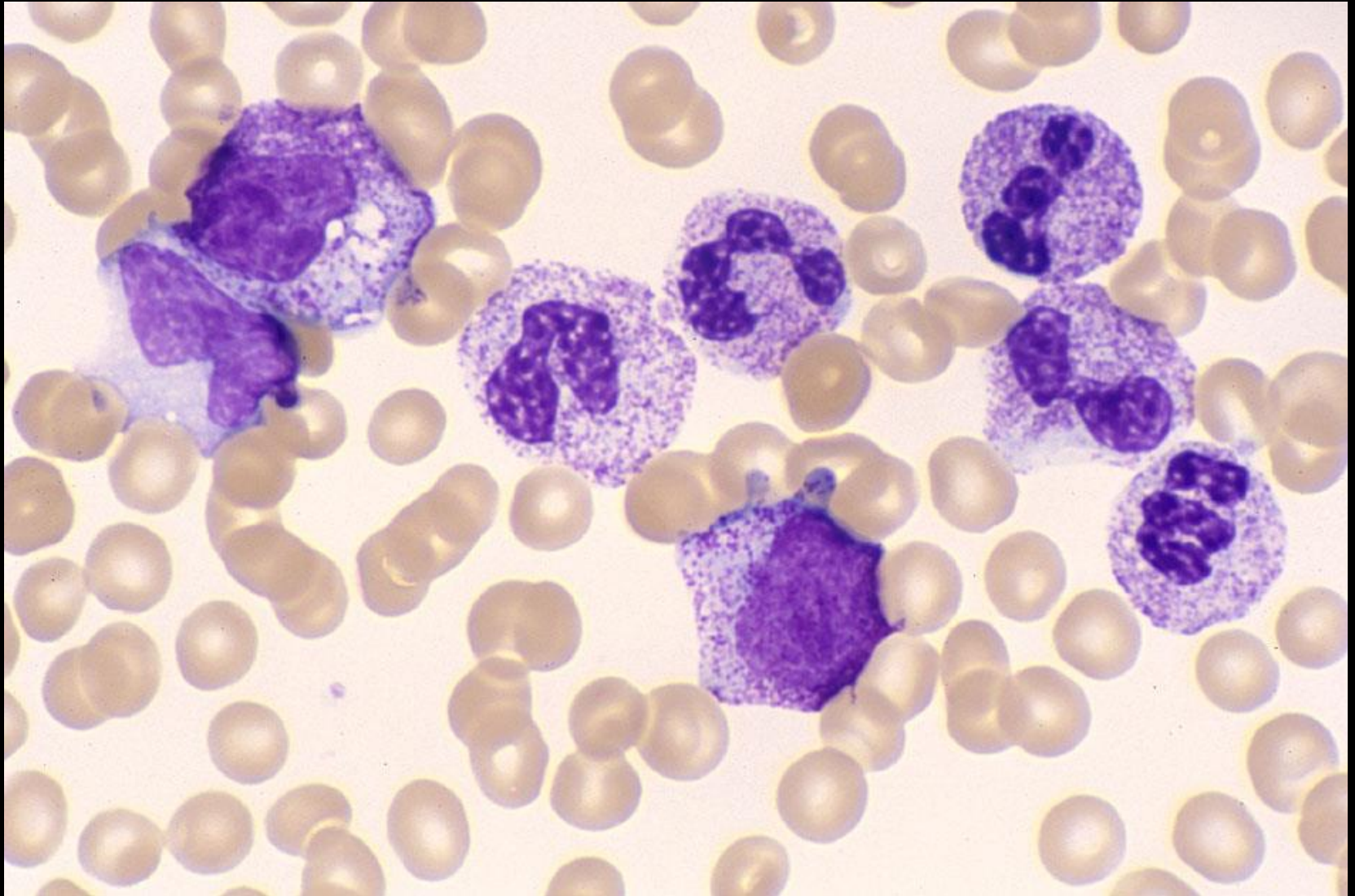
- Hairy Cell Leukaemia (HCL) variant

CASE STUDY

Male 3 years: Neuroblastoma/on chemotherapy

• Hb	79	(107-136)	g/L
• RBC	2.84	(3.86-5.01)	$\times 10^{12}/L$
• MCV	77.8	(73-85)	fL
• MCH	27.8	(24.8-29.9)	pg
• MCHC	350	(329-359)	g/L
• RDW-CV	14.2	(12.1-15.6)	%
• WBC	62.1	(4.9-12.8)	$\times 10^9/L$
• Plats	139	(214-483)	$\times 10^9/L$

Case study (26)



CASE STUDY

Blood film comments:

Red cells normal for age

Film consistent with G-CSF therapy

CASE STUDY

DIAGNOSIS:

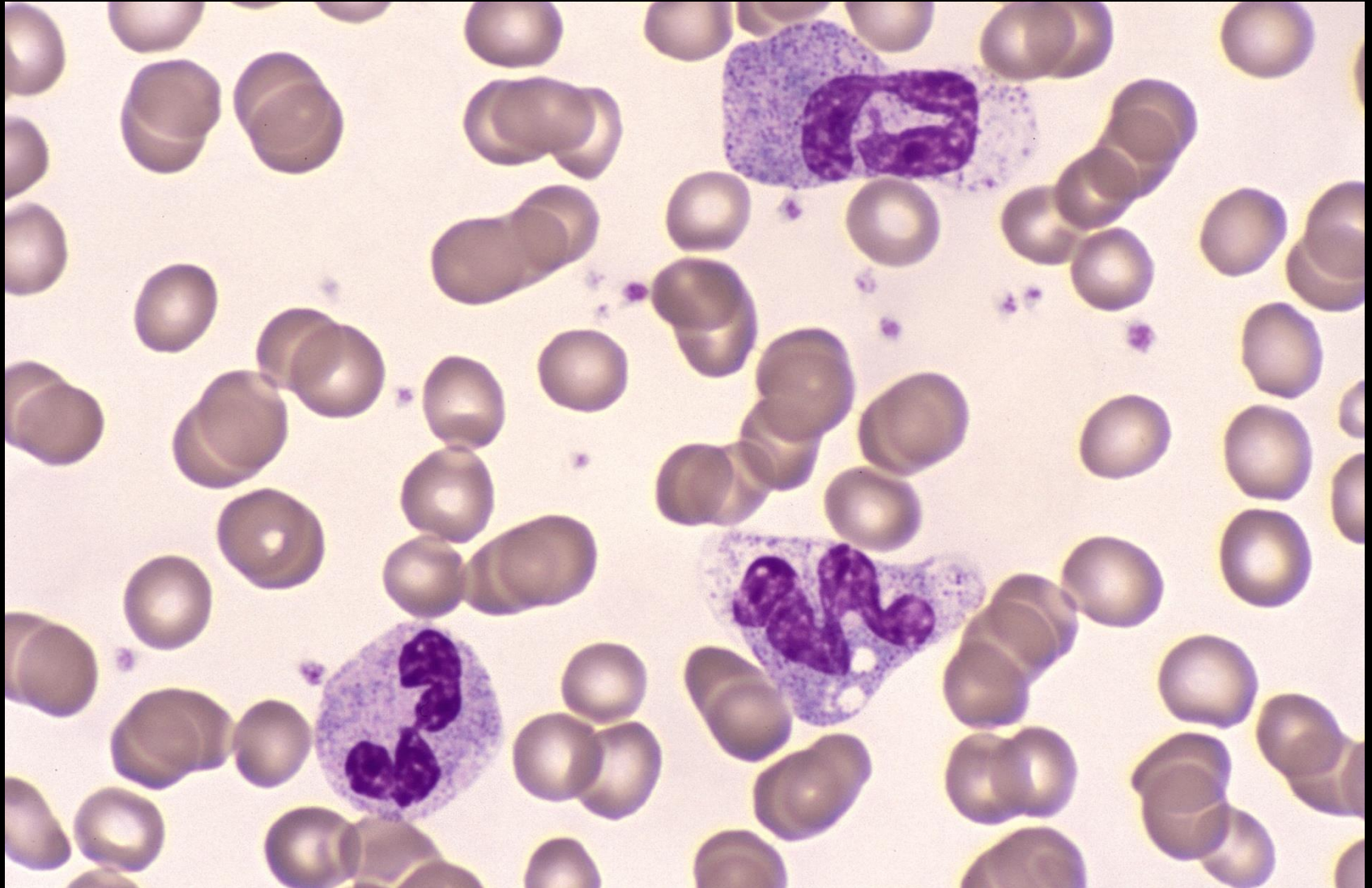
- Cytokine therapy (G-CSF)

CASE STUDY

Female 3 years: High fever for 7 days (unresponsive to antibiotics)

• Hb	97	(107-136)	g/L
• RBC	3.67	(3.86-5.01)	$\times 10^{12}/L$
• MCV	80.0	(73-85)	fL
• MCH	26.5	(24.8-29.9)	pg
• MCHC	324	(329-359)	g/L
• RDW-CV	13.2	(12.1-15.6)	%
• WBC	10.5	(4.9-12.8)	$\times 10^9/L$
• Plats	506	(214-483)	$\times 10^9/L$
• ESR	85	mms / hour	

Case study (27)



CASE STUDY

Blood film comments:

Moderate hypergranulated neutrophils

Slight vacuolation

Moderate rouleaux

Neutrophils show cytoplasmic swelling, a feature seen in Kawasaki disease

CASE STUDY

DIAGNOSIS:

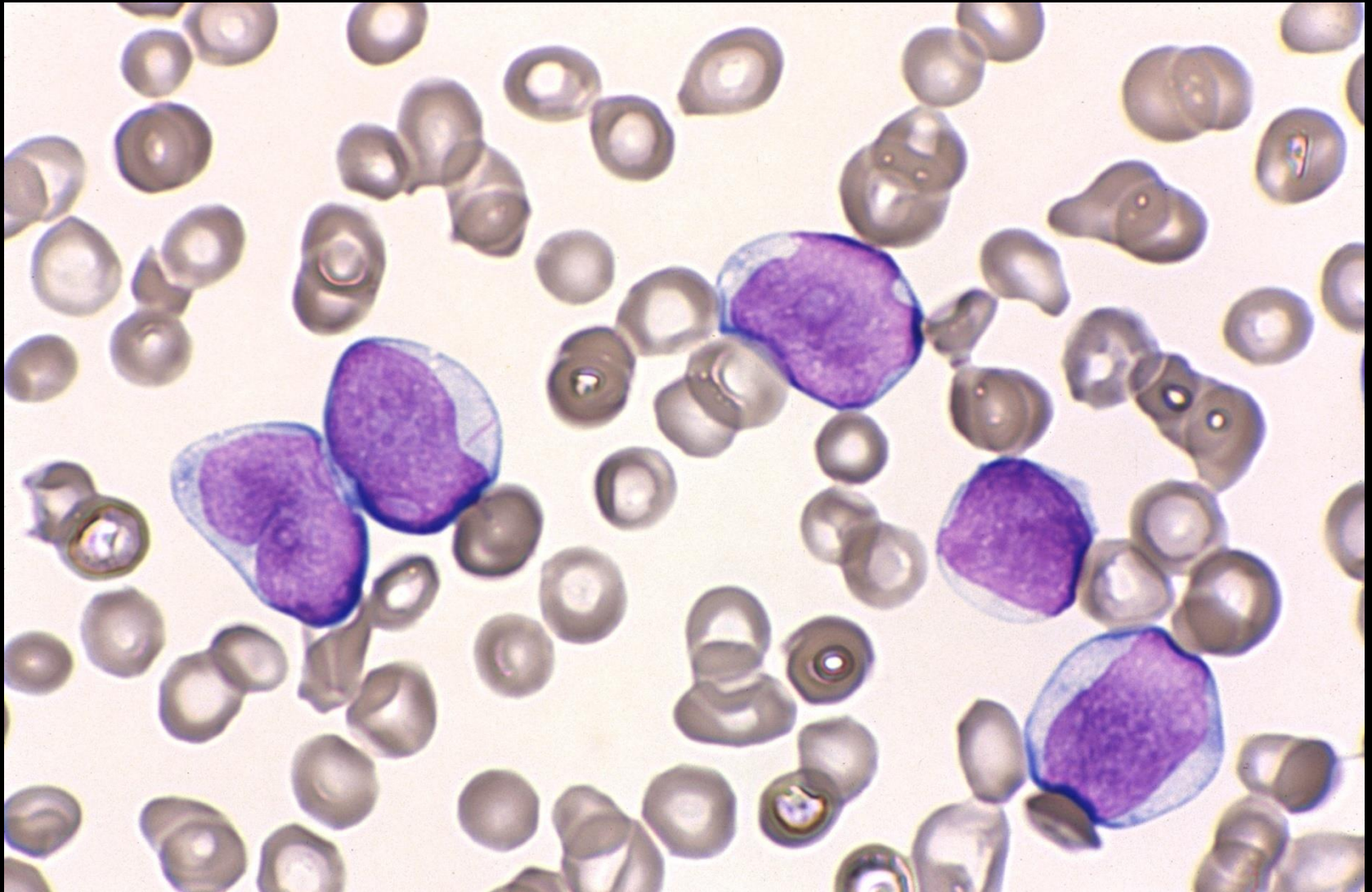
- Suggestive of Kawasaki disease
- Check clinical picture of child
- Check blood cultures

CASE STUDY

Female 23 years: Anaemia/bruising

• Hb	103	(115-165)	g/L
• RBC	3.61	(3.80-5.80)	$\times 10^{12}/L$
• MCV	85.0	(80-100)	fL
• MCH	27.5	(26.5-33.0)	pg
• MCHC	329	(310-360)	g/L
• RDW-CV	15.2	(12.0-14.5)	%
• WBC	13.5	(3.50-11.00)	$\times 10^9/L$
• Plats	18	(150-400)	$\times 10^9/L$

Case study (28)



CASE STUDY

Blood film comments:

Slight anisocytosis

87% blast cells present

Auer rods present

CASE STUDY

Immunophenotype:

- CD13⁺, CD33⁺, CD34^{+/-}, CD117⁺

Cytogenetics

- -7

CASE STUDY

DIAGNOSIS:

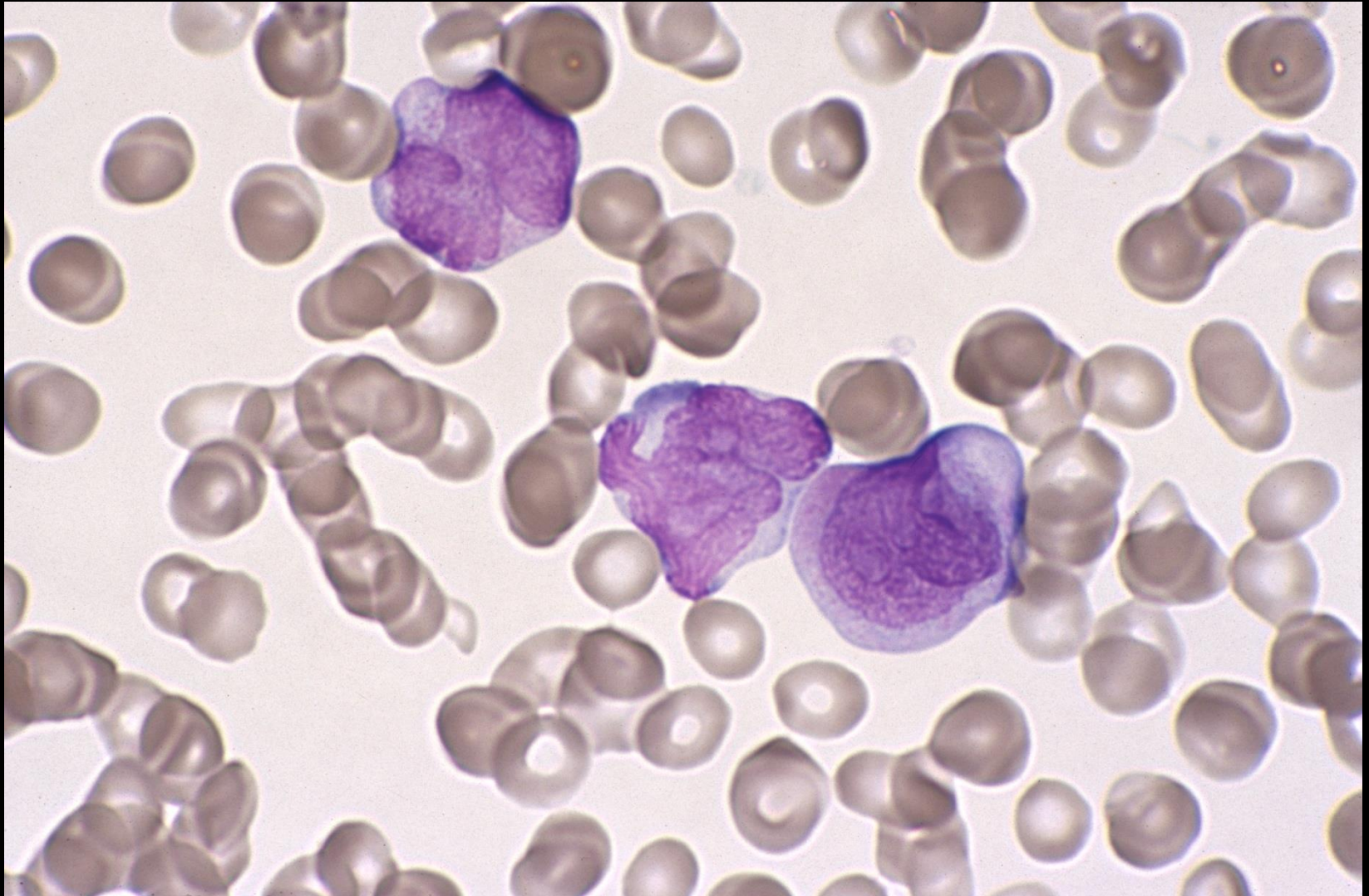
- Acute myeloid leukaemia not otherwise specified:
Acute myeloblastic leukaemia without maturation

CASE STUDY

Male 45 years: Anaemia/bruising

• Hb	95	(130-180)	g/L
• RBC	2.92	(4.50-6.50)	$\times 10^{12}/L$
• MCV	92.8	(80-100)	fL
• MCH	32.5	(26.5-33.0)	pg
• MCHC	351	(310-360)	g/L
• RDW-CV	14.7	(12.0-14.5)	%
• WBC	3.2	(3.50-11.0)	$\times 10^9/L$
• Plats	81	(150-400)	$\times 10^9/L$
• D-DIM LIA	9.65	ug/ml	

Case study (29)



CASE STUDY

Blood film comments:

Slight anisocytosis

Hypogranular promyelocytes present

17% abnormal promyelocytes

Occasional Auer rod present

CASE STUDY

Immunophenotype:

- HLA-DR⁻, CD13⁺, CD33⁺, CD34⁻

Cytogenetics

- t(15;17)

CASE STUDY

DIAGNOSIS:

- Acute myeloid leukaemia with recurrent genetic abnormalities:

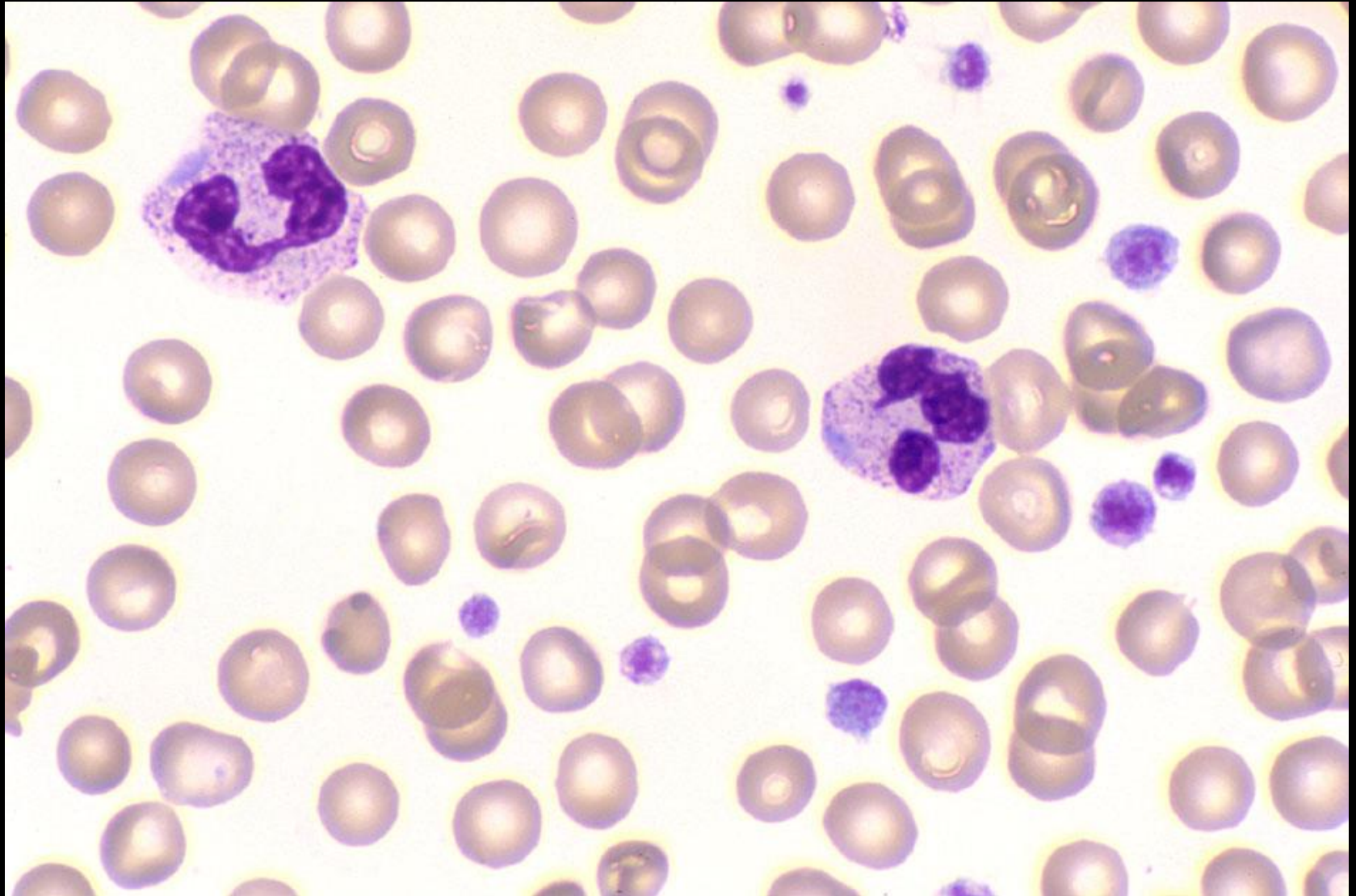
Acute promyelocytic leukaemia (APL) with $t(15;17)(q22;q12)$ and variants

CASE STUDY

Male 2 years: Routine blood count

• Hb	115	(104-132)	g/L
• RBC	5.35	(3.88-5.13)	$\times 10^{12}/L$
• MCV	68.6	(70-83)	fL
• MCH	21.5	(23.1-29.4)	pg
• MCHC	313	(323-354)	g/L
• RDW-CV	13.4	(12.3-17.0)	%
• WBC	10.9	(5.4-13.6)	$\times 10^9/L$
• Plats	133	(205-553)	$\times 10^9/L$

Case study (30)



CASE STUDY

Blood film comments:

Slight microcytes

Slight hypochromasia

Large platelets present

The neutrophils contain Döhle bodies

CASE STUDY

DIAGNOSIS:

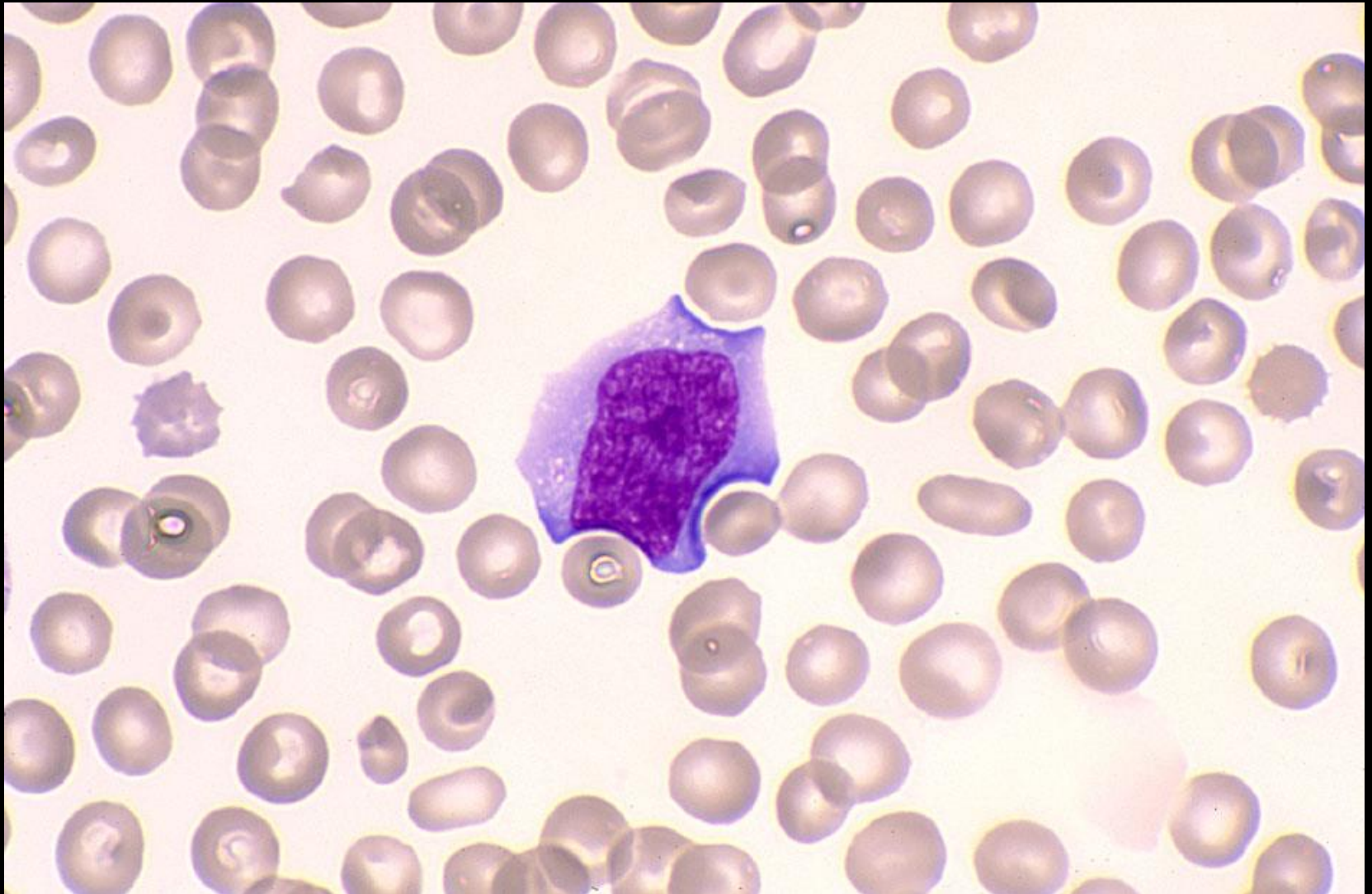
- May-Hegglin anomaly

CASE STUDY

Male 18 months: Petechial rash in an otherwise healthy child

• Hb	131	(104-132)	g/L
• RBC	4.79	(3.88-5.13)	$\times 10^{12}/L$
• MCV	79.5	(70-83)	fL
• MCH	27.3	(23.1-29.4)	pg
• MCHC	344	(323-354)	g/L
• RDW-CV	13.1	(12.3-17.0)	%
• WBC	11.6	(5.4-13.6)	$\times 10^9/L$
• Plats	3	(205-553)	$\times 10^9/L$

Case study (31)



CASE STUDY

Blood film comments:

Normal red blood cells

Reactive lymphocytes present

Occasional large platelet seen

Film suggestive of ITP

CASE STUDY

- Bone marrow biopsy shows normal numbers of megakaryocytes
- Thrombocytopenia secondary to peripheral platelet destruction

CASE STUDY

DIAGNOSIS:

- Immune Thrombocytopenic Purpura (ITP)

Gillian Rozenberg Training Workshops

THANK YOU FOR ATTENDING
THIS HAEMATOLOGY
MORPHOLOGY WORKSHOP

SAFE TRIP HOME
&
TAKE CARE

