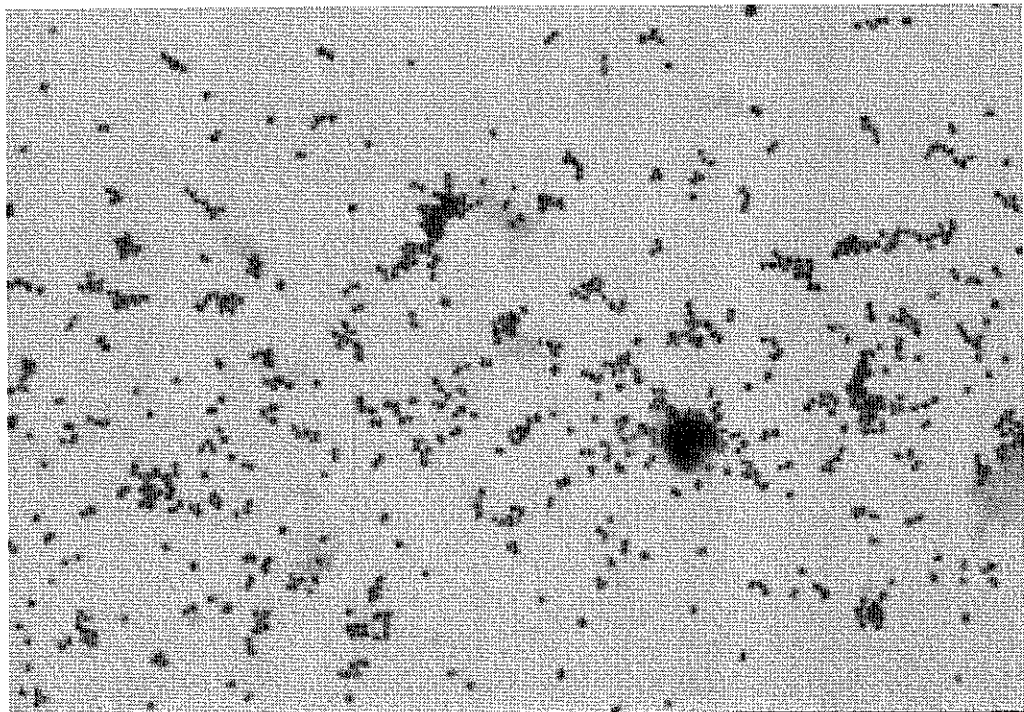


Gram Stain



D5-15

**Discussion**

This was a simulated joint fluid specimen from a 22-year-old female with a swollen painful left knee. This slide contained *Neisseria gonorrhoeae*, which stained as gram-negative diplococci and cocci. Leukocytes in the specimen can help guide if decolorization was adequate. Polymorphonuclear leukocytes were present.

Stain Reaction	Referees (70)		Participants(1493)	
	No.	%	No.	%
Gram-negative	66	94.3	1272	85.2
Gram-positive	4	5.7	221	14.8
<b>Morphology</b>				
Diplococci	49	70.0	875	58.7
Cocci	18	25.7	421	28.2
Bacilli	-	-	5	0.3
Cocco-bacilli	-	-	38	2.5
Cocci in clusters	2	2.9	66	4.4
Cocci in pairs/chains	1	1.4	87	5.8
<b>Polymorphonuclear leukocytes</b>				
Polymorphonuclear leukocytes Absent	1	1.4	37	2.5
Polymorphonuclear leukocytes Present	69	98.6	1451	97.5