

TRAINING UPDATE

Lab Location: GEC, SGMC & WAH
Department: Core Lab

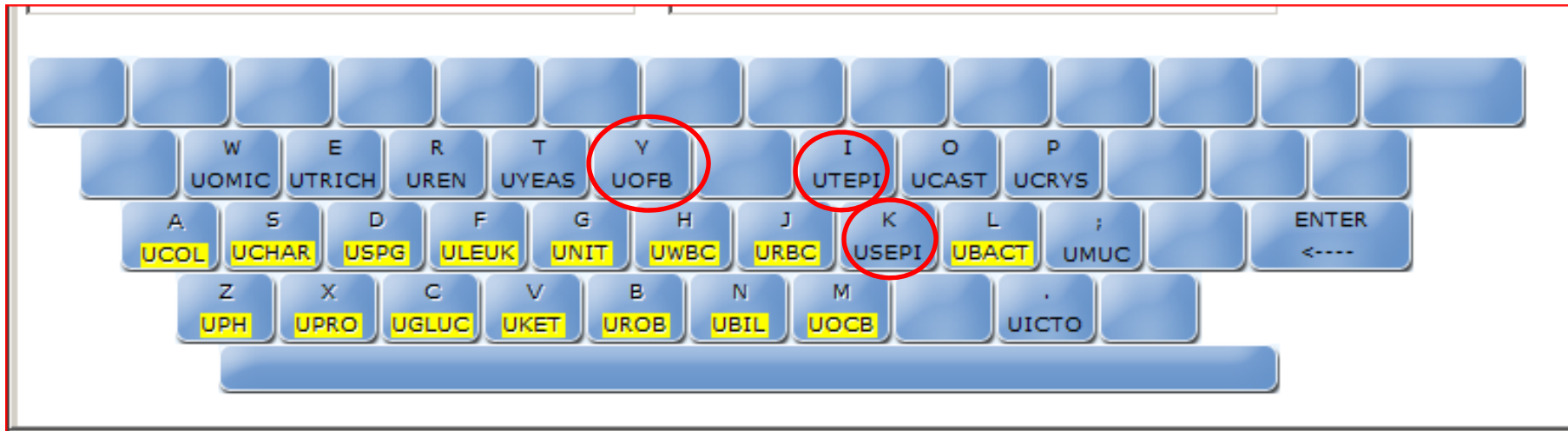
Date Distributed: 9/27/2018
Due Date: 10/16/2018
Implementation: 10/16/2018

DESCRIPTION OF PROCEDURE REVISION

Name of procedure:																		
Microscopic Examination of Urine, Manual Method SGAH.U05 v4																		
Description of change(s):																		
<p>Revisions were made to make this method match the automated testing methods.</p> <p>Notes:</p> <ol style="list-style-type: none">SOP has always included reporting squamous and transitional epithelial cells but the UMIC keyboard only had a key for 'epi' (there was no way to differentiate these). These have been added as 2 separate keys (K&I).Oval fat bodies were mentioned in the clinical indication section but not include in reporting or on UMCI keyboard. It has been added (key Y)																		
<table border="1"><thead><tr><th>Section</th><th>Reason</th></tr></thead><tbody><tr><td>6</td><td>Remove individual section labeling instructions and add general one</td></tr><tr><td>7.3</td><td>Add conical tubes</td></tr><tr><td>8.1</td><td>Clarify Epi cells, add oval fat body, remove redundant power field columns</td></tr><tr><td>10.5</td><td>Review data moved from section 6</td></tr><tr><td>11.1</td><td>Add ranges to match other methods</td></tr><tr><td>12.1</td><td>Delete use of acetic acid to lyse RBCs</td></tr><tr><td>15</td><td>Updated to new standard wording</td></tr><tr><td>16</td><td>Add GEC log</td></tr></tbody></table>	Section	Reason	6	Remove individual section labeling instructions and add general one	7.3	Add conical tubes	8.1	Clarify Epi cells, add oval fat body, remove redundant power field columns	10.5	Review data moved from section 6	11.1	Add ranges to match other methods	12.1	Delete use of acetic acid to lyse RBCs	15	Updated to new standard wording	16	Add GEC log
Section	Reason																	
6	Remove individual section labeling instructions and add general one																	
7.3	Add conical tubes																	
8.1	Clarify Epi cells, add oval fat body, remove redundant power field columns																	
10.5	Review data moved from section 6																	
11.1	Add ranges to match other methods																	
12.1	Delete use of acetic acid to lyse RBCs																	
15	Updated to new standard wording																	
16	Add GEC log																	
<p>This revised SOP will be implemented on October 16, 2018</p>																		

Document your compliance with this training update by taking the quiz in the MTS system.

UMIC Keyboard



Note - Renal epi cells have NOT been changed, they are still reported using the R key

Technical SOP

Title	Microscopic Examination of Urine, Manual Method	
Prepared by	Leslie Barrett	Date: 8/25/2010
Owner	Robert SanLuis	Date: 11/25/2014

Laboratory Approval		Local Effective Date:
Print Name and Title	Signature	Date
<i>Refer to the electronic signature page for approval and approval dates.</i>		

Review		
Print Name	Signature	Date

TABLE OF CONTENTS

1. Test Information.....2
 2. Analytical Principle3
 3. Specimen Requirements.....3
 4. Reagents4
 5. Calibrators/Standards4
 6. Quality Control4
 7. Equipment And Supplies6
 8. Procedure6
 9. Calculations.....8
 10. Reporting Results And Repeat Criteria.....8
 11. Expected Values.....10
 12. Clinical Significance.....10
 13. Procedure Notes17
 14. Limitations Of Method17
 15. Safety18
 16. Related Documents18
 17. References.....18
 18. Revision History18
 19. Addenda19

1. TEST INFORMATION

Assay	Method/Instrument	Local Code
Microscopic Examination of Urine	Manual / Microscope	UMIC

Synonyms/Abbreviations
N/A

Department
Urinalysis

2. ANALYTICAL PRINCIPLE

Normal urine may contain small numbers of cells and other formed elements from the entire length of the genito-urinary tract. These may include casts and epithelial cells from the nephron; epithelial cells from the pelvis, ureters, bladder, and urethra; mucous threads and spermatozoa from the prostate. A few erythrocytes and leukocytes apparently reach the urine by diapedesis from any part of the urinary tract. Such structures, if present in large quantities, usually indicate a pathological condition. The urine sample is first concentrated by centrifugation and then the urine sediment is examined microscopically to determine the types and quantities of its constituents.

There is evidence that in random urinalysis screening, urines that are yellow and clear, and have negative chemical reactions, have a markedly low yield on microscopic examination. Those urines with negative chemical reactions by dipstick test will not be tested for microscopic analysis.

3. SPECIMEN REQUIREMENTS

3.1 Patient Preparation

Component	Special Notations
Fasting/Special Diets	N/A
Specimen Collection and/or Timing	Normal procedures for collecting and storing urine may be used for samples to be analyzed by this method.
Special Collection Procedures	Clean catch specimen preferred. Refer to Urine Collection, Client Service procedure.
Other	If Urine Collection Kit is not used, submit to Laboratory within 2 hours of collection.

3.2 Specimen Type & Handling

Criteria	
Type	A freshly voided urine sample collected by the “clean catch” method.
-Preferred	
-Other Acceptable	Random urine
Collection Container	Clean or sterile container
Volume	15 mL
- Optimum	
- Minimum	2 mL
Transport Container and Temperature	Urine Collection Kit (Urine Analysis Preservative Tube preferred) or container at room temperature.
Stability & Storage Requirements	Room Temperature: 24 hours in Urine Analysis Preservative Tube 2 hours for other containers
	Refrigerated: 24 hours
	Frozen: Unacceptable

Criteria	
Timing Considerations	None
Unacceptable Specimens	Specimens that are unlabeled, improperly labeled, or those that do not meet the stated criteria are unacceptable. Request a recollection and cancel the test with the appropriate LIS English text code for “test not performed” message. Example: Wrong collection-UNAC. Document the request for recollection in the LIS.
Compromising Physical Characteristics	Grossly contaminated specimens will be rejected and appropriate personnel notified.
Other Considerations	If the specimen has been refrigerated, allow the urine to warm to room temperature before testing. Before examination, the urine should be mixed to suspend the sediment for accurate sampling. After testing, samples will be held until the next successful QC performance.

NOTE: Labeling requirements for all reagents, calibrators and controls include: (1) Open date, (2) Substance name, (3) Lot number, (4) Date of preparation, (5) Expiration date, (6) Initials of tech, and (7) Any special storage instructions. Check all for visible signs of degradation.

4. REAGENTS

Not applicable

5. CALIBRATORS/STANDARDS

Not applicable

6. QUALITY CONTROL

6.1 Controls Used

Controls	Supplier and Catalog Number
Human Urinalysis Control Level I	KOVA-Trol™ HYCOR® Cat. No. 91017
Human Urinalysis Control Level II	KOVA-Trol™ HYCOR® Cat. No. 87128
Human Urinalysis Control Level III	KOVA-Trol™ HYCOR® Cat. No. 87328

6.2 Control Preparation and Storage

Control	KOVA-Trol Levels I, II and III
Preparation	Level I: Reconstitute with exactly 15 mL of Reagent Grade water.

	<p>Level II and III: Reconstitute with exactly 60 mL of Reagent Grade water.</p> <p>All Levels: Allow the reconstituted material to stand at room temperature for 15 minutes and gently rotate the bottle intermittently until all of the material has dissolved.</p>
Slide Preparation	<ol style="list-style-type: none"> 1. Centrifuge urine control in a conical bottom centrifuge tube for 5 minutes at 400 RCF (g). 2. Discard the supernatant urine and thoroughly mix the urine sediment with the remaining urine supernatant. Place a small drop on a glass slide and coverslip. 3. Scan ten (10) high-power fields and report RBCs and WBCs in the same manner as patient specimens. Enter results on the Urinalysis QC Log.
Storage/Stability	Once reconstituted, the controls remain stable for 7 days at 2-8°C in its original capped vial.

6.3 Frequency

Microscopic QC is performed once per day.

6.4 Tolerance Limits and Criteria for Acceptable QC

Acceptable ranges are recorded on the top of the Urinalysis QC sheet.

IF ...	THEN...
Any control does not produce the expected result	<p>The test is invalid. Do not report patient results. Repeat testing.</p> <p>Do not report patient results until acceptable QC results are obtained.</p> <p>If repeat testing does not produce acceptable QC, then notify supervisor immediately.</p>

6.5 Documentation

All quality control results are recorded on the Urinalysis QC form.

6.6 Quality Assurance Program

- Training must be successfully completed and documented prior to performing this test.
- The laboratory participates in CAP proficiency testing.

7. EQUIPMENT and SUPPLIES

7.1 Assay Platform

Not applicable

7.2 Equipment

Brightfield microscope equipped with low power (10X) and high power (40X) objectives
 Centrifuge, 400g

7.3 Supplies

Single plain glass microscope slides
 22x22mm coverslips
 Disposable plastic transfer pipette
Plastic conical urinalysis tubes

8. PROCEDURE

NOTES:

For all procedures involving specimens, buttoned lab coats, gloves, and face protection are required minimum personal protective equipment. Report all accidents to your supervisor.

If the specimen has been refrigerated, allow the urine to warm to room temperature before testing.

8.1	Test Run												
1.	Centrifuge a portion of the urine in a conical bottom centrifuge tube for 5 minutes at 400 RCF (g).												
2.	Discard the supernatant urine and thoroughly mix the urine sediment with the remaining urine supernatant. Place a small drop on a glass slide and coverslip.												
3.	Scan approximately ten low-power fields as well as ten high-power fields and report as follows: Amorphous material: report as 1+ to 3+ depending on the amount of material present per low power field (10X). <table border="1" style="margin-left: 20px;"> <thead> <tr> <th># clusters seen</th> <th>Grade as</th> <th>Report</th> </tr> </thead> <tbody> <tr> <td>1-4</td> <td>Few</td> <td>1+</td> </tr> <tr> <td>5-10</td> <td>Moderate</td> <td>2+</td> </tr> <tr> <td>>10</td> <td>Many</td> <td>3+</td> </tr> </tbody> </table>	# clusters seen	Grade as	Report	1-4	Few	1+	5-10	Moderate	2+	>10	Many	3+
# clusters seen	Grade as	Report											
1-4	Few	1+											
5-10	Moderate	2+											
>10	Many	3+											

8.1	Test Run																					
	<p>Crystals: report by range seen per high power field (40X). Refer to a urine sediment atlas for the identification of the crystals. A second technologist should confirm any abnormal crystals before reporting.</p> <table border="1"> <thead> <tr> <th># seen</th> <th>Grade as</th> <th>Report</th> </tr> </thead> <tbody> <tr> <td>0-5</td> <td>Few</td> <td>FEW</td> </tr> <tr> <td>6-10</td> <td>Moderate</td> <td>1+</td> </tr> <tr> <td>11-20</td> <td>Many</td> <td>2+</td> </tr> <tr> <td>21-100</td> <td>Many</td> <td>3+</td> </tr> </tbody> </table>	# seen	Grade as	Report	0-5	Few	FEW	6-10	Moderate	1+	11-20	Many	2+	21-100	Many	3+						
# seen	Grade as	Report																				
0-5	Few	FEW																				
6-10	Moderate	1+																				
11-20	Many	2+																				
21-100	Many	3+																				
	<p>Bacteria: Report, as 1+ to 4+ according to whether there is a small, moderate or large number per average HPF.</p>																					
	<p>Trichomonas: Do not quantitate. Report only as present, if applicable.</p>																					
	<p>Epithelial cells: Report range of Squamous cells present per low power field (10X). Renal and transitional cells are graded under high power field (40X)</p> <table border="1"> <thead> <tr> <th># seen</th> <th>Grade as</th> <th>Report</th> </tr> </thead> <tbody> <tr> <td>0-2</td> <td>Occasional</td> <td>Occ.</td> </tr> <tr> <td>2-5</td> <td>Few</td> <td>1+</td> </tr> <tr> <td>6-10</td> <td>Moderate</td> <td>2+</td> </tr> <tr> <td>11-20</td> <td>Moderate</td> <td>3+</td> </tr> <tr> <td>21-100</td> <td>Many</td> <td>4+</td> </tr> <tr> <td>TNTC</td> <td>Many</td> <td>4+</td> </tr> </tbody> </table>	# seen	Grade as	Report	0-2	Occasional	Occ.	2-5	Few	1+	6-10	Moderate	2+	11-20	Moderate	3+	21-100	Many	4+	TNTC	Many	4+
# seen	Grade as	Report																				
0-2	Occasional	Occ.																				
2-5	Few	1+																				
6-10	Moderate	2+																				
11-20	Moderate	3+																				
21-100	Many	4+																				
TNTC	Many	4+																				
	<p>Casts: Identify and report as range of casts (i.e. 10-15) per average low power field (10X).</p>																					
	<p>Mucus: Report as 1+ to 4+ mucus threads per average low power field (10X).</p>																					
	<p>RBC: Report as range seen per high power field (40X)</p> <table border="1"> <thead> <tr> <th># seen</th> <th>Report</th> </tr> </thead> <tbody> <tr> <td>0-2</td> <td>0-2</td> </tr> <tr> <td>2-5</td> <td>2-5</td> </tr> <tr> <td>6-10</td> <td>6-10</td> </tr> <tr> <td>11-20</td> <td>11-20</td> </tr> <tr> <td>21-100</td> <td>21-100</td> </tr> <tr> <td>TNTC</td> <td>TNTC</td> </tr> </tbody> </table>	# seen	Report	0-2	0-2	2-5	2-5	6-10	6-10	11-20	11-20	21-100	21-100	TNTC	TNTC							
# seen	Report																					
0-2	0-2																					
2-5	2-5																					
6-10	6-10																					
11-20	11-20																					
21-100	21-100																					
TNTC	TNTC																					

8.1	Test Run														
	<p>WBC: Report as range per high power field (40X).</p> <table border="1" style="margin-left: 20px;"> <thead> <tr> <th># seen</th> <th>Report</th> </tr> </thead> <tbody> <tr> <td>0-2</td> <td>0-2</td> </tr> <tr> <td>2-5</td> <td>2-5</td> </tr> <tr> <td>6-10</td> <td>6-10</td> </tr> <tr> <td>11-20</td> <td>11-20</td> </tr> <tr> <td>21-100</td> <td>21-100</td> </tr> <tr> <td>TNTC</td> <td>TNTC</td> </tr> </tbody> </table> <p>Report any other (than those listed above) microscopic elements as 1+, 2+, 3+ using these guidelines:</p> <p style="margin-left: 40px;">(1+) = less than ¼ of the High Power Field had the element present. (2+) = ¼ to ½ of the High Power Field has element present (3+) = greater than ½ of the High Power Field had the element present</p> <p>Note: Spermatozoa on males or adult females is not reported.</p>	# seen	Report	0-2	0-2	2-5	2-5	6-10	6-10	11-20	11-20	21-100	21-100	TNTC	TNTC
# seen	Report														
0-2	0-2														
2-5	2-5														
6-10	6-10														
11-20	11-20														
21-100	21-100														
TNTC	TNTC														
4.	Refer to Addenda A “Urinalysis Keyboard: Macroscopic and Microscopic Result Entry” for instructions to release results.														
5.	<p>A summary of microscope power settings:</p> <table border="1" style="margin-left: 20px;"> <thead> <tr> <th colspan="2" style="text-align: center;">Power Field Instructions for Microscopy</th> </tr> <tr> <th style="text-align: center;">High Power Field (HPF) 40X</th> <th style="text-align: center;">Low Power Field (LPF) 10X</th> </tr> </thead> <tbody> <tr> <td>RBCs and WBCs</td> <td>Squamous Epithelial Cells</td> </tr> <tr> <td>Renal and Transitional Epithelial Cells</td> <td>All Casts</td> </tr> <tr> <td>Bacteria / Yeast / Crystals / Oval Fat Bodies</td> <td>Mucus</td> </tr> </tbody> </table>	Power Field Instructions for Microscopy		High Power Field (HPF) 40X	Low Power Field (LPF) 10X	RBCs and WBCs	Squamous Epithelial Cells	Renal and Transitional Epithelial Cells	All Casts	Bacteria / Yeast / Crystals / Oval Fat Bodies	Mucus				
Power Field Instructions for Microscopy															
High Power Field (HPF) 40X	Low Power Field (LPF) 10X														
RBCs and WBCs	Squamous Epithelial Cells														
Renal and Transitional Epithelial Cells	All Casts														
Bacteria / Yeast / Crystals / Oval Fat Bodies	Mucus														

NOTE: Results of dipstick examination must be correlated with the microscopic exam.

9. CALCULATIONS

Not applicable

10. REPORTING RESULTS AND REPEAT CRITERIA

10.1 Guidelines for comparing Multistix 10 SG with urine microscopic exam.

Multistix 10 SG	Microscopic Findings
Leukocyte esterase – Positive	Look for 10 WBC/HPF or trichomonas. It is possible that the WBC's are lysed and won't be seen. High levels of albumin (500 mg/dL) may interfere with the test results. Large amounts of ascorbic acid decreases the sensitivity of the chemical tests.

Multistix 10 SG	Microscopic Findings
Nitrite – Positive	Look for evidence of infection: bacteria and 10 WBC/HPF This will not always be observable. A concentration as low as 0.05 mg/dL of nitrite will produce a slightly pink color on the strip. Large amounts of ascorbic acid decreases the sensitivity of the chemical test.
Protein - Positive	Look for large numbers of WBCs, RBCs or bacteria. Casts are formed of a different protein than albumin and may not give a positive result. Certain drugs may interfere and give a false positive result.
Blood and Hemoglobin	We do not differentiate between blood and hemoglobin on our reports. A large amount of occult blood on the strip would indicate a large number of RBCs on microscopic, but these RBCs may be hemolyzed and you would not see many cells.

Notes:

The presence of any questionable constituents should be brought to the supervisor's attention and not released. The specimen should be refrigerated until it can be reviewed by senior laboratory personnel.

Do not report **spermatozoa**.

Cystine, Cholesterol, Leucine, Bilirubin, Tyrosine, Sulfa and Hippuric acid are abnormal crystals. The specimen should be refrigerated until it can be reviewed by senior laboratory personnel or reviewed by a Pathologist.

10.2 Rounding

N/A

10.3 Units of Measure

See each analyte in section 8.

10.4 Clinically Reportable Range (CRR)

N/A

10.5 Review Patient Data

Review patient results for unusual patterns, trends or distributions, such as an unusually high percentage of abnormal results.

10.6 Repeat Criteria

None

11. EXPECTED VALUES

11.1 Reference Ranges

WBC	0-2/HPF
RBC	0-2/HPF
Bacteria	Negative
Renal Epithelial Cells	0/HPF
Squamous Epithelial Cells	0-2/LPF
Transitional Epithelial Cells	0/HPF
Hyaline Casts	0-1/LPF
All other Casts	0/LPF
Mucus	0/LPF
Crystals	None seen/HPF
Yeast, Oval Fat Body and Trichomonas	Negative/HPF

11.2 Critical Values

None established

11.3 Standard Required Messages

None established

12. CLINICAL SIGNIFICANCE

12.1 Cells

Erythrocytes

Smooth biconcave disks approximately 7u in diameter and 2u thick, pale or yellowish appearance. In alkaline or hypotonic urine, the red cells swell and can lyse. Lysed cells, "ghost cells", are faint, colorless circles and are actually empty red cell membranes. In hypertonic urine, red cells will crenate. Swollen and crenated RBC's are sometimes mistaken for WBC's.

The presence of a positive test for occult blood is often helpful. Red cells are refractile and when the fine adjustment is turned up or down so the red cells are on a different plane, red cells appear as black circles.

Normally RBC's do not appear in urine, although a few are not considered abnormal. In females, the presence of red cells can be a result of menstrual contamination.

Injury or rupture of blood vessels of the kidney or urinary tract will release red cells into the urine. Hematuria will also occur in cases of internal bleeding.

Leukocytes

White blood cells are usually spherical and can appear as dull gray or a greenish-yellow color. They may occur singly or in clumps and usually can be identified by their granules or lobes of their nucleus. WBC's shrink in hypertonic urine, and swell up or are rapidly lysed in hypotonic or alkaline urine. Granules in swollen cells may demonstrate Brownian movement. These cells are referred to as "glitter cells". An increase in WBC's in the urine is associated with an inflammatory process in or adjacent to the urinary tract.

Epithelial Cells

Squamous epithelial cells are easily recognized as large, flat, irregularly shaped cells, which contain a small central nucleus and abundant cytoplasm.

Renal tubular epithelial cells are slightly larger than leukocytes and contain a large, round nucleus. They may be flat, cuboidal or columnar.

Transitional epithelial cells are two to four times as large as white cells. They may be round, pear-shaped or may have a tail-like projection. Normally, a few epithelial cells are found in the urine as a result of the normal sloughing off of old cells. A marked increase indicates an inflammation of that portion of the urinary tract from the cells derived. Squamous epithelial cells occur principally in the urethra and vagina, renal tubulars in the renal tubules and transitional cells in the urinary tract from the pelvis of the kidney to the upper portion of the urethra.

12.2 Crystals - Commonly Found in Acid Urine

Uric Acid

Uric acid crystals occur in many different shapes, but the most characteristic forms are the diamond or rhomboid prism and the rosette, which consists of many crystals clustered together. They may occasionally have six sides and this form is sometimes erroneously identified as cystine.

Uric acid crystals are usually stained with urinary pigments and can therefore be yellow or reddish-brown in color. Under polarized light, uric acid crystals will take on a variety of colors. The crystals are soluble in sodium hydroxide and insoluble in hydrochloric acid, acetic acid and alcohol.

The presence of uric acid crystals can be normal. Pathological conditions in which uric acid crystal in urine are found include gout, high purine metabolism, acute febrile conditions, chronic nephritis and Lesch-Nyhan syndrome.

Calcium Oxalate

Colorless octahedral or "envelope" shaped crystals, which look like small squares crossed by intersecting diagonal lines. They rarely appear as oval spheres or

biconcave disks when viewed from the side. When focusing on the typical calcium oxalate crystal, the “X” of the crystal will be very prominent. They are frequently found in acid urine, but occasionally can be found in alkaline urine. They are soluble in hydrochloric acid but insoluble in acetic acid.

Calcium oxalate crystals can be present normally in the urine after ingestion of various oxalate-rich foods. Increased amounts of calcium oxalate crystals suggest conditions such as oxalate calculi, ethylene glycol poisoning, diabetes mellitus, liver disease, severe chronic renal disease, and intake of large doses of Vitamin C.

Amorphous Urates

Urate salts of sodium, potassium, magnesium and calcium present in a non-crystalline, amorphous form. They have yellow-red granular appearance and are soluble in alkali. They have no clinical significance.

Hippuric Acid

Yellow-brown or colorless elongated prisms or plates. They may be so thin as to resemble needles and often cluster together. These crystals are rarely seen in the urine and have practically no clinical significance.

Sodium Urate

Colorless or yellowish slender prisms (not pointed at the ends) occurring in sheaves or clusters. They are soluble at 60°C, only slightly soluble in acetic acid. They have no clinical significance.

Calcium Sulfate

Long, thin, colorless needles or prisms that are extremely soluble in acetic acid. These crystals are rarely seen in the urine and have no clinical significance.

Cystine

Colorless, refractile, hexagonal plates with equal on unequal side appearing singly, on top of each other or in clusters. They frequently have a laminated appearance. Cystine crystals are soluble in hydrochloric acid and alkali, especially ammonia (this solubility in ammonia helps to differentiate cystine from colorless six-sided uric acid crystals). They are insoluble in acetic acid, alcohol, acetone, ether, and boiling water. Cystine can be detected chemically with a sodium cyanide-sodium nitroprusside test.

The presence of cystine crystals in the urine is always important. They occur in patients with congenital cystinosis, congenital cystinuria, and they can form calculi.

Leucine

Oily, highly refractile, yellow or brown spheroids with radial and concentric striations. Leucine is soluble in hot acetic acid, hot alcohol, and in alkali. They are insoluble in hydrochloric acid.

These crystals are found in urine of patients with maple syrup urine disease, Oasthouse urine disease, and in serious liver disease. Leucine and tyrosine crystals are frequently present together in serious liver disease.

Tyrosine

Very fine, highly refractile needles occurring in sheaves or clusters. They are soluble in the presence of bilirubin. Tyrosine is soluble in ammonium hydroxide, and hydrochloric acid but insoluble in acetic acid.

These crystals occur in serious liver disease, tyrosinosis and Oasthouse urine disease.

Cholesterol

Large, flat transparent plates with notched corners, exhibiting a variety of colors under polarized light. At times, cholesterol crystals are found as a film on the surface of the urine instead of in the sediment. They are soluble in chloroform, ether, and hot alcohol.

The presence of cholesterol crystals in urine indicates excessive tissue breakdown. They may also be present in chyluria, which is the result of either thoracic or abdominal obstruction to lymph drainage.

Sulfa and other drug crystals

Sulfonamide drugs precipitate out as sheaves of needles, usually with eccentric binding, that are clear or brown in color. They are soluble in acetone and can be verified by a lignin test.

Radiograph dyes can crystallize out as pleomorphic needles, which can occur singly or in sheaves, occasionally seen with brown spheres, and is birefringent under polarized light. These dyes are very dense and will result in an elevated specific gravity.

Bilirubin may crystallize out as red or reddish-brown needles or granules. They are soluble in chloroform, acetone, acid, and alkali, but are insoluble in alcohol, and ether.

12.3 Crystals – Commonly Found in Alkaline Urine

Triple Phosphate

Colorless prisms with three to six sides which frequently have oblique ends. They may precipitate in feathery or fern-like crystals. They are soluble in acetic acid.

They may be found in normal urine or in pathological conditions, including chronic pyelitis, chronic cystitis, enlarged prostate and when urine is retained in the bladder.

Amorphous Phosphates

Non-crystalline amorphous sediment with no definite shape. They are soluble in acetic acid, which helps distinguish them from amorphous urate. They have no clinical significance.

Calcium Carbonate

Small, colorless crystals appearing in dumbbell or spherical forms, or in large granular masses. They are larger than amorphous and, when in clumps, they appear to have a dark color. They are soluble in acetic acid and have no clinical significance.

Calcium Phosphate

Long, thin, colorless prisms with one pointed end, arranged as rosettes or stars, or appearing as needles. They may also form irregular, granular plates, which float on the surface of the urine. They are soluble in dilute acetic acid. They may be present in normal urine, but they may also form calculi.

Ammonium Biurate

Yellow-brown spherical bodies with long, irregular spicules often described as “thorn apples”. They may also occur as yellow-brown spheroids without spicules, although this form is not common. Occasionally, they are found in acid urine. Ammonium biurates dissolve by warming, and are soluble in acetic acid, with the formation of colorless uric acid crystals after standing. The addition of sodium hydroxide will liberate the ammonia. They are abnormal only in freshly voided urine.

12.4 Casts

Urinary casts are formed in the lumen of the tubules of the kidney. They can form as a result of the precipitation or gelation of Tamm-Horsfall mucoprotein, the clumping of cells or other material within a protein matrix, the adherence of cells or material to the matrix or by conglutination of material within the lumen. Factors involved in case formation include urinary stasis, increased acidity, high solute concentration, and the presence of abnormal ionic or protein constituents.

Cast formation usually takes place in the distal and collecting tubules. Casts will dissolve in alkaline urine. They have nearly parallel sides and rounded or blunted ends, and they vary in size and shape according to the tubules in which they were formed. They may be convoluted, straight or curved, and vary in length. Casts are always renal in origin, and they are important indicators of intrinsic renal disease.

Hyaline

Colorless, homogenous, transparent casts composed of gelled Tamm-Horsfall protein usually found with rounded ends. They have a low refractile index and must be viewed under low light. They may contain some inclusions, which were incorporated while in the kidney. A few hyaline casts may be found in normal urine and increased amounts are frequently present following physical exercise and physiologic dehydration.

Red Cell

May contain only a few RBC's in a protein matrix or there may be many cells packed close together with no visible matrix. If the RBC's are still intact, the cast is termed a

red cell cast. If the cast has degenerated to a reddish-brown granular cast, then it is termed a hemoglobin or blood cast.

Red cell casts mean renal hematuria and are always pathologic. They are usually diagnostic of glomerular disease caused by acute glomerulonephritis, lupus nephritis, Good Pasture's Syndrome, SBE, and renal trauma. They can also be present in renal infraction, severe pyelonephritis, right-sided congestive heart failure, renal valve thrombosis, and periarteritis nodosa.

White Cell

May contain a few WBC's or many white cells tightly packed together. The majority of white cells are PMN's. If the cells are intact, the nuclei may be clearly visible, but, as they degenerate, the cell membranes disappear and the cast becomes granular. White cell casts are present in renal infection and non-infectious inflammation.

Granular

May be the results of degeneration of cellular cast, or they may represent the direct aggregate of serum proteins into a matrix of Tamm-Horsfall mucoprotein. Finely granular casts contain fine granules, gray or pale yellow in color. Coarsely granular casts contain larger granules that are darker in color, often giving the cast a black color.

Granular casts almost always indicate a significant renal disease, although they may present for a short time following strenuous exercise.

Epithelial

Epithelial cells may be arranged in parallel rows or haphazardly. They may vary in size, shape, or stage of degeneration. Epithelial casts may form as a result of stasis and the desquamation of renal tubular epithelial cells. They occur after exposure to nephrotoxic agents or viruses (CMV, hepatitis), in severe chronic renal disease, and in the rejection of a kidney allograft.

Waxy

Waxy casts have a very high refractive index, are yellow, gray or colorless, and have a smooth, homogeneous appearance. They frequently occur as short broad casts with blunt or broken ends, and often have cracked edges. They may result from the degeneration of granular casts.

Conditions in which waxy casts are found include severe chronic renal failure, malignant hypertension, renal amyloidosis, and diabetic nephropathy.

Fatty

Casts that have incorporated free fat droplets or oval fat bodies. Fatty casts are seen when there is fatty degeneration of the tubular epithelium.

12.5 Miscellaneous Structures

Bacteria

The presence of bacteria is easily recognized under high power. The presence of large numbers of bacteria in freshly voided urine is usually indicative of a urinary tract infection.

Yeast

Smooth, colorless, usually ovoid cells with doubly refractive walls. They can vary in size and often show budding. They are insoluble in acid and alkali. Yeast may be found in urinary tract infections or as a result of skin contamination.

Spermatozoa

Oval bodies with long, thin, delicate tails. They may be present in males after epileptic convulsions, nocturnal emissions, diseases of the genital organ, and in spermatorrhea. Spermatozoa in males or adult females is **NOT** reported.

Mucous Threads

Long, thin wavy threads of ribbon-like structures that may show faint longitudinal striations. They are present in normal urine in small numbers, but they may be abundant in the presence of inflammation or irritation of the urinary tract.

Oval Fat Bodies and free Fat Droplets

Highly refractile globules, frequently yellow-brown in appearance. Oval fat bodies are usually defined as renal tubular cells containing fat droplets. Oval Fat bodies exhibit the Maltese Cross phenomenon when viewed with polarized light. Fat may be present in the urine as a result of fatty degeneration of the tubules, in nephrotic syndrome, diabetes, eclampsia, renal poisoning, fractures of the long bones, and injuries crushing the subcutaneous fat.

12.6 Parasites

Trichomonas vaginalis

Flagellated organism about the size of a leukocyte. It should not be reported unless it is mobile. It is frequently accompanied by the presence of WBC's and epithelial cells.

Enterobius vermicularis

Pinworm ova and, occasionally, the female adult. Very characteristic in shape, having one flat and one rounded side.

Schistosoma haematobium

These eggs have a light yellowish-brown transparent shell with a distinct terminal spine. The eggs measure between 112 to 170 μm by 40 to 70 μm .

12.7 Artifacts

Starch

Irregularly shaped, round or oval, highly refractive bodies that appear to exhibit the “Maltese Cross” phenomenon under polarized light. These are distinguished from Oval Fat bodies in that they are irregular in shape and are larger in size, being several times larger than an RBC. Most commonly due to contamination with powder.

Fibers

Long and flat threads, usually dark at the edges. They may be contaminants from clothing, diapers, toilet paper, etc.

13. PROCEDURE NOTES

- **FDA Status:** Approved/cleared
 - **Validated Test Modifications:** None
- A. Improper preservation of specimens when testing is delayed may yield inaccurate results.
 - B. Specimens that are not properly mixed before centrifuging and/or after decanting may yield inaccurate quantitation of microscopic elements.
 - C. Casts have a tendency to locate near the edge of the slide.
 - D. Red blood cells, white blood cells, and crystals are quantified per high power field; casts are quantified per low power field.
 - E. Correct light adjustment is essential to view the sediment accurately. The light must be reduced enough to provide contrast to the various unstained structures and the background liquid. The iris diaphragm should be opened or closed to provide the contrast. The condenser should not be “racked down” for this contrast. Especially difficult to visualize are hyaline casts, mucus and various cells.
 - F. Since KOVA stain is used only to enhance the visibility of the microscopic examination, all quantification of urine sediment is done unstained.

14. LIMITATIONS OF METHOD

14.1 Analytical Measurement Range (AMR)

N/A

14.2 Precision

N/A

14.3 Interfering Substances

N/A

14.4 Clinical Sensitivity/Specificity/Predictive Values

N/A

15. SAFETY

Refer to your local and corporate safety manuals and Safety Data Sheet (SDS) for detailed information on safety practices and procedures and a complete description of hazards.

16. RELATED DOCUMENTS

1. Laboratory Quality Control Program
2. Laboratory Safety Manual
3. Quest Diagnostics Records Management Procedure
4. Urine Collection, Client Service procedure
5. Manual Urinalysis QC Form (AG.F133)
6. Clinitek 500 QC Log (AG.F402) GEC only

17. REFERENCES

1. Valenstein, PN & Keopke, JA, 1984, "Unnecessary Microscopy in Routine Urinalysis", AJCP 82 (4): 444-448.
2. Ringsrud & Linne, *Urinalysis and Body Fluids A ColorText and Atlas*, St. Louis, Mosby, 1995
3. Jacobs, Demett, Finley, Horvat, Kasten & Tizer, *Laboratory Test Handbook*, 1994.
4. Bartlett, RC & Kaczmarczyk, LA, 1984, "Usefulness of Microscopic Examination on Urinalysis", AJCP 82 (6): 713-716.
5. McPherson and Fincus, *Henry's Clinical Diagnosis and Management by Laboratory Methods*, Philadelphia, Saunders Elsevier 2007. (27) 412-419.

18. REVISION HISTORY

Version	Date	Section	Reason	Reviser	Approval
			Supersedes SOP U009.002		
000	9/21/11	3.2	Add retention of specimen until next QC	L Barrett	C Reidenauer
000	9/21/11	6.3	Change QC frequency to once a day	A Chini	C Reidenauer
000	9/21/11	7.2	Add centrifuge	L Barrett	C Reidenauer
000	9/21/11	8.1	Correct LPF/HPF to 10X and 40X, revise centrifugation speed	A Chini	C Reidenauer
000	9/21/11	12.5	Define reporting of spermatozoa, add Maltese Cross phenomenon in oval fat bodies	C Reidenauer	C Reidenauer
000	9/21/11	12.7	Add distinguishing characteristics of starch vs oval fat bodies	C Reidenauer	C Reidenauer
000	9/21/11	15	Update to standard content	L Barrett	C Reidenauer
000	9/21/11	17	Reference #5 added	C Reidenauer	C Reidenauer

Version	Date	Section	Reason	Reviser	Approval
000	9/21/11	19	Add Addenda	L Barrett	C Reidenauer
001	11/25/14		Update owner	L Barrett	R SanLuis
001	11/25/14	3.1	Add urine collection kit	L Barrett	R SanLuis
001	11/25/14	6.2	Add reconstitution information	L Barrett	R SanLuis
001	11/25/14	8.1	Remove specific volume to centrifuge	L Barrett	R SanLuis
001	11/25/14	16	Add QC form and collection SOP	L Barrett	R SanLuis
001	11/25/14	Addenda A	Update LIS screen shots & instructions	A Chini	R SanLuis
001	11/25/14	Footer	version # leading zero's dropped due to new EDCS in use as of 10/7/13	L Barrett	R SanLuis
2	7/19/16	Header	Add other sites	L Barrett	R SanLuis
2	7/19/16	3.2	Add preservative tube information	A Chini	R SanLuis
2	7/19/16	8.1	Add microscope power summary	A Chini	R SanLuis
2	7/19/16	10.1	Add reporting notes	A Chini	R SanLuis
3	8/20/18	6	Remove individual section labeling instructions and add general one	L Barrett	R SanLuis
3	8/20/18	7.3	Add conical tubes	D Collier	R SanLuis
3	8/20/18	8.1	Clarify Epi cells, add oval fat body, remove redundant power field columns	L Barrett	R SanLuis
3	8/20/18	10.5	Review data moved from section 6	L Barrett	R SanLuis
3	8/20/18	11.1	Add ranges to match other methods	L Barrett	R SanLuis
3	8/20/18	12.1	Delete use of acetic acid to lyse RBCs	D Collier	R SanLuis
3	8/20/18	15	Update to new standard wording	L Barrett	R SanLuis
3	8/20/18	16	Add GEC log	D Collier	R SanLuis

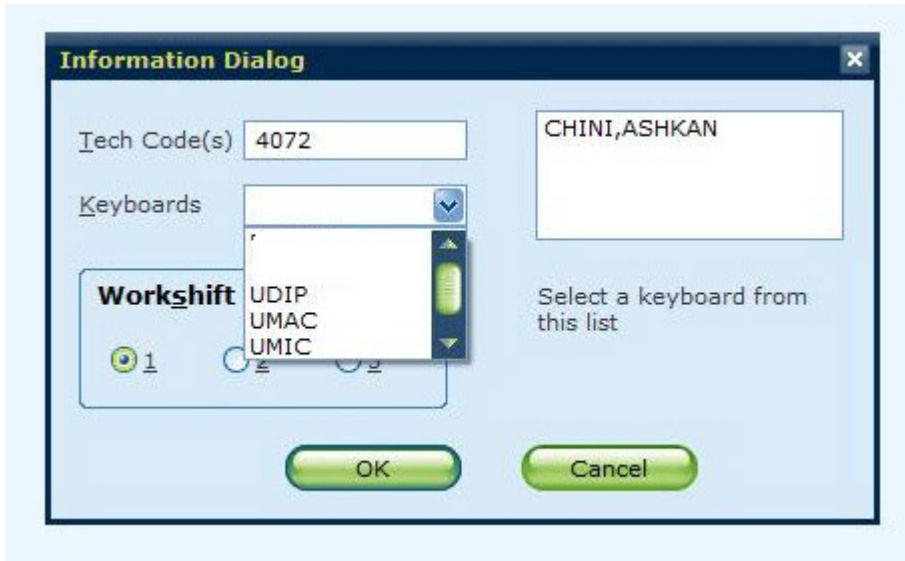
19. ADDENDA

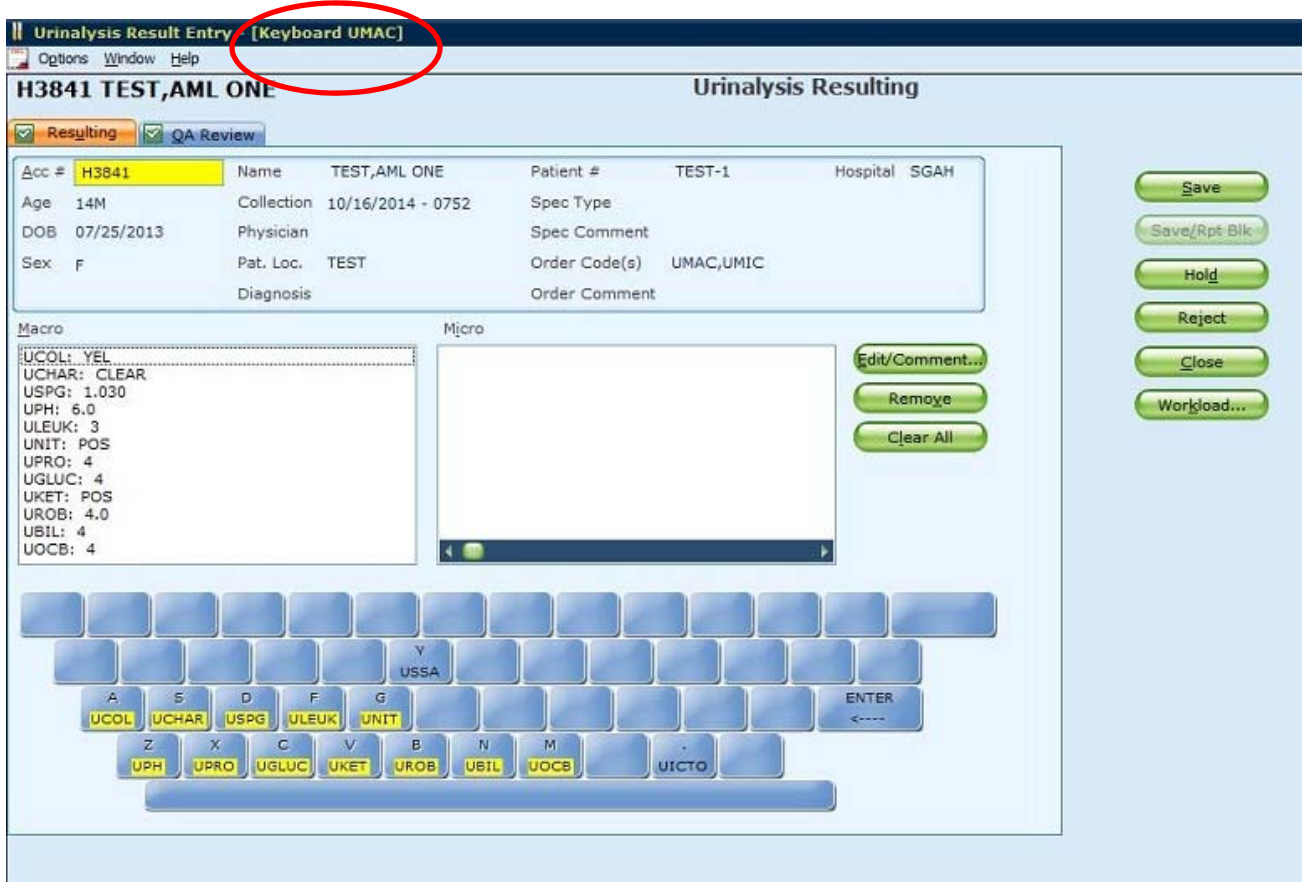
A. Urinalysis Keyboard: Macroscopic and Microscopic Result Entry

Addenda A

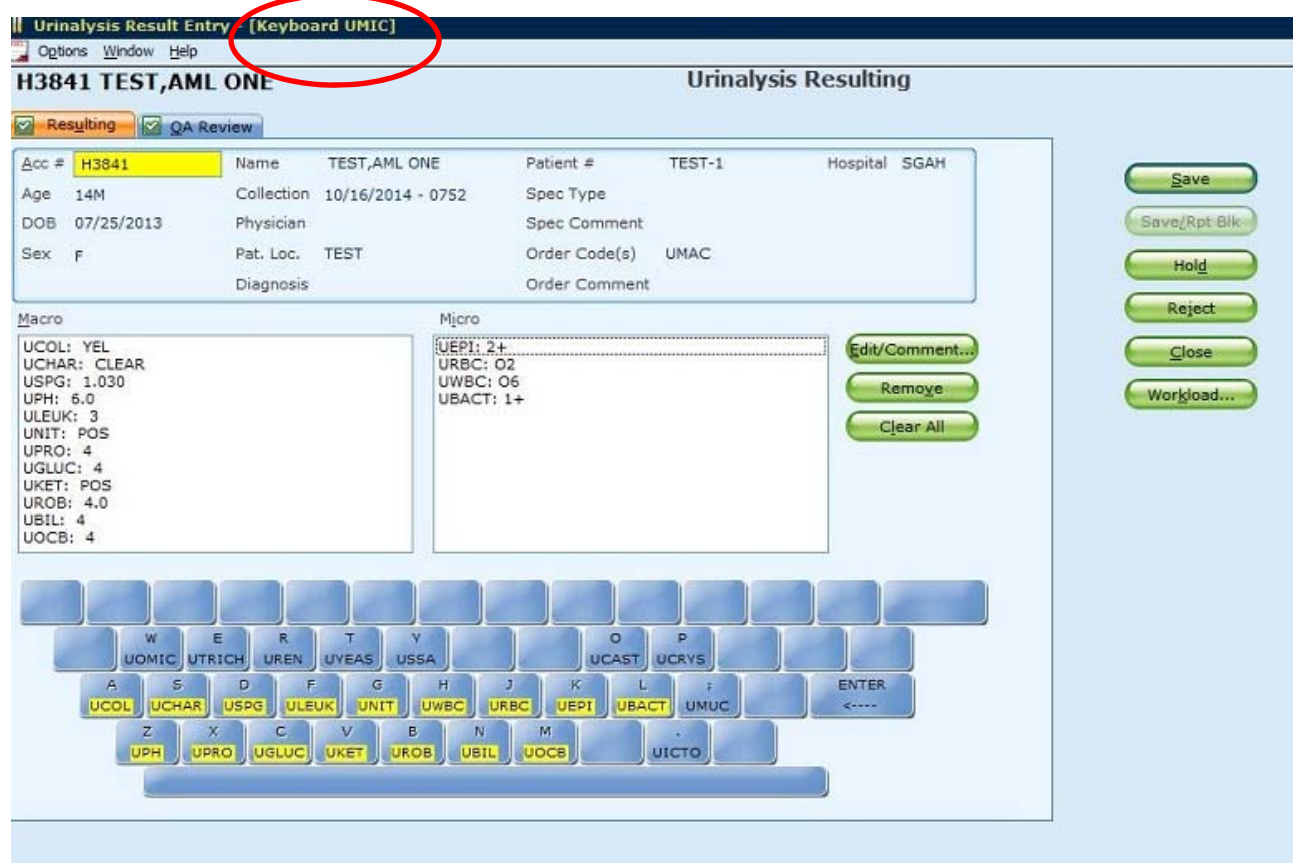
Urinalysis Keyboard: Macroscopic and Microscopic Result Entry

1. Log into Sunquest, select the **Urinalysis Result Entry**. The following information dialog box will be displayed demonstrating the different keyboards. Choose **UMAC** or **UMIC**.





2. To result the macroscopic urinalysis, select the **UMAC** keyboard, type in the Accession # and press **ENTER**.
 - The automated analyzer results for the macroscopic dipstick will be displayed (see above).
 - Select **QA Review** to review the results and click on the **SAVE** button to save and file the results.
 - Orders for urine microscopic test will be automatically ordered if necessary.
 - If resulting manually, depress the urine component key and select the appropriate result for the urine component. Select **ENTER** and continue resulting other urine components.



3. To result the urine microscopic select the **UMIC** keyboard, type in the Accession # then press **ENTER**. The urine macroscopic results will show up along with the keyboard to result the urine microscopic.
4. The urine microscopic may be resulted by clicking on the keyboard displayed on the screen with the mouse or by using the corresponding keys on the keyboard.
 - There are four (4) components that are required for each microscopic analysis:
 - White blood cells
 - Red blood cells
 - Epithelial cells
 - Bacteria
5. To append a comment, select the test code, click on the **EDIT/COMMENT** button and enter free text and/or an English text code in the Comment box.
6. A Quality Assurance check must be performed before saving the results. To save and file the urine microscopic click on the **SAVE** button.