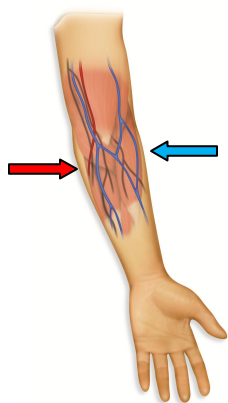


## Acceptable Sites for Venipuncture

#3207



There is a lot a phlebotomist must know about the anatomy of the arm in order to make good choices about site selection. All veins are not fair game. Some veins are perilously close to arteries, nerves, and tendons. Inadvertently damaging one of these structures is a real possibility if you don't know the anatomy of the arm. Serious injury to the patient can result if an artery is nicked or a nerve is provoked by a stray needle. Lawsuits brought by injured patients can cost money, time, and peace of mind. By knowing the anatomy of the arm and understanding the limitations to vein selection, phlebotomists and their employers can protect their patients from injury and avoid phlebotomy-related lawsuits.

On Page Two you will find an illustration of the arm with the veins, nerves, and arteries indicated. Let's focus our discussion on the antecubital area of the arm and the veins most often selected for blood specimen collection. Veins in this area have an advantage over veins of the hand in that they are generally larger, have better blood flow, and are less likely to move or "roll" during the venipuncture. All veins in the antecubital area are not first-choice veins however. The basilic vein runs very close to the brachial artery and branches of the median nerve. With the arm in "anatomical position," (i.e. with the thumb pointing away from the body as is the left arm pictured here) notice how the basilic vein, brachial artery, and nerves run close together on the side of the arm nearest the patient's body. (indicated by a red arrow in the illustration above) It is easy to see how a stray needle in that area could cause serious injury to a patient.

Because a blood collection from the basilic vein is so risky, other veins in the antecubital area are much more suitable. The basilic vein should not be the first vein selected if there are other antecubital veins from which to choose. Whenever possible, another vein should be selected. CLSI's (Clinical and Laboratory Standards Institute) document GP41 advises to avoid draws to the basilic vein and the medial aspect (inward, toward the body) of the median cubital vein because the brachial artery and the median nerve are so close. Draws from these areas should only be considered if no other vein is more prominent. In a legal context, if the basilic vein is selected even though there were other, less risky veins and the patient is injured, the phlebotomist and his/her employer could be found liable should the injured patient file a lawsuit. What veins are better choices for venipuncture? The center and lateral aspect (outer, toward the cephalic vein) of the median cubital vein, median cephalic vein, and accessory cephalic vein are all better choices for vein selection.

The median cubital can be found close to the center of the antecubital area. It has good support from surrounding structures, which means it is less likely to "roll." On bariatric patients this vein may be quite deep, so a firm deep pressure may be needed to palpate the median cubital vein. The median cephalic vein is also a good choice because it is generally not close to an artery or nerve. The cephalic veins run along the lateral (outer side) of the arm. While some veins have a lesser likelihood of being near a nerve or artery, keep in mind each individual has their own unique anatomy, and the location of the structures can be slightly different. Because of that, it is good practice to determine the location of the pulse in the antecubital area while palpating for vein selection.

Can the basilic vein ever be chosen for venipuncture? Yes it can, as long as a thorough assessment of both arms has been conducted and there are no other antecubital options available. When it has been determined no other vein is available, there are precautions that must be taken before trying to access the basilic vein. Find the location of the brachial artery in relation to the basilic vein by feeling for the pulse. If it rests perilously close to the basilic vein, the risk of accessing the basilic may be too great. Is the basilic vein easily visible and palpable? You cannot probe around looking for it, so do not ever attempt to access the basilic vein if unable to feel it. Here are the rules for accessing the basilic vein:

- There must be no other antecubital options available after a complete survey of both arms
- It must be palpable and preferably also visible
- It must not be so close to the brachial artery that it could be nicked or punctured

Are there any other areas that are off limits to the phlebotomist? Yes, the front and side of the wrist, which have a network of vulnerable nerves, tendons, and arteries. It is unsafe and against CLSI standards to attempt blood specimen collection from veins in the palm-side and thumb-side of the wrist. Hand veins are available for venipuncture as an alternative to antecubital veins but are fragile, so use care with these collections. A syringe or a winged collection device with syringe (to control vacuum) is best for collections from the hand.

# Blood Collector's ATM

Abbreviated Teaching Modules  
for staff development, competency, and classroom

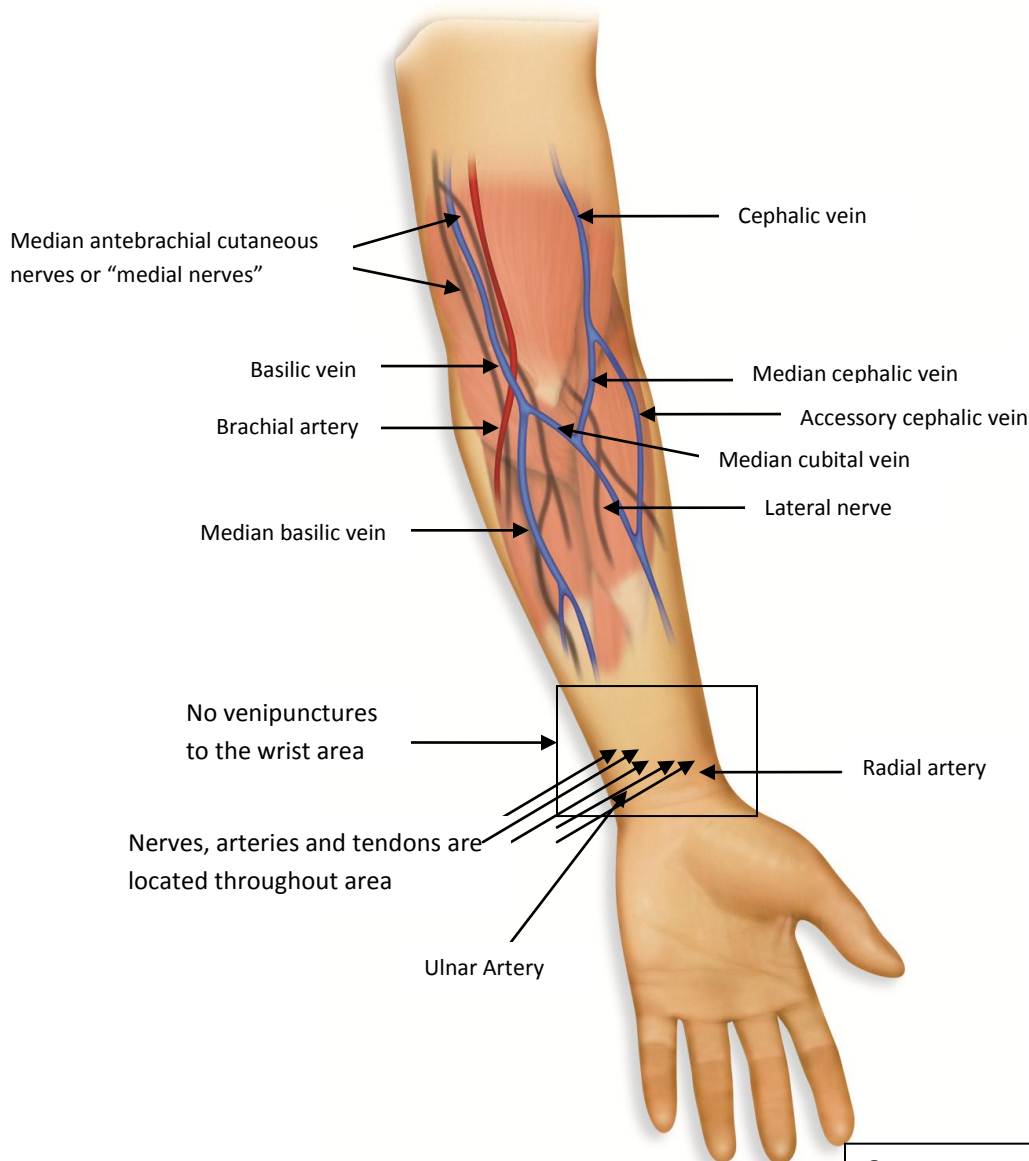


Probing is never allowed when attempting to access a vein. Probing can be defined as blindly moving the needle through the tissues in hope of finding the vein. The entire edge of a needle's bevel is extremely sharp, not just the tip, so any sideways movement of the needle damages tissue. If that tissue happens to be an artery or nerve, the patient could be injured. When an artery has been nicked there could be rapid swelling from below the insertion site. A suspected arterial nick requires additional pressure at the puncture site. When a needle provokes a nerve, the patient experiences a sharp shooting pain. Should that occur, the needle must be removed immediately, even if blood is filling the tube.

Needle relocation is limited to inserting the needle slightly deeper or withdrawing it a bit. That's it. Side to side movement when trying to access the basilic vein goes against CLSI standards. Practices that stray from CLSI standards leave the phlebotomist and their employer unable to successfully defend themselves should a patient be injured and seek legal remedy.

The picture below illustrates the approximate locations of the veins, arteries, and nerves of the arm. Make sure you understand the anatomy of the arm before you stick a needle into another patient and always adhere to CLSI's venipuncture standards.

## Anatomy of the arm





## Acceptable Sites for Venipuncture

#3207

### Test your knowledge:

1. Name the vein associated with the greatest risk of patient injury.
  - a) cephalic
  - b) median
  - c) basilic
2. What must be true before attempting to access the basilic vein?
  - a) no other antecubital veins are available
  - b) it is palpable and/or visible
  - c) it is not close to the artery
  - d) all of the above
3. What must be considered before attempting to access a vein on the palm side of the wrist?
  - a) the size of the vein is large enough to accommodate a 23 gauge needle
  - b) a butterfly with a syringe must be used
  - c) there are no veins available elsewhere
  - d) none of the above
4. What soft tissue structures are found in the wrist area?
  - a) small veins, tendons, nerves, and the radial and ulnar arteries
  - b) multiple small veins that are acceptable for venipuncture
  - c) the basilic and cephalic veins
5. What measures should a phlebotomist take if a patient complains of a sharp "electric-like" pain?
  - a) complete the collection if blood is filling the tube, then remove the needle
  - b) remove the needle immediately
  - c) pull back the needle slightly and probe side to side to find the vein
  - d) reassure the patient that the procedure is almost over
6. Which of these statements is true?
  - a) the cephalic veins and median veins are preferred before the basilic
  - b) a sharp "electrical" type pain could indicate a nerve has been provoked by the needle
  - c) rapid swelling of the arm at the insertion site could indicate an artery has been nicked or punctured
  - d) all of the above are true
7. True or False  
The basilic vein is the first vein of choice for obtaining blood specimens.

Name: \_\_\_\_\_ Date: \_\_\_\_\_  
Facility/Supervisor \_\_\_\_\_ Dept: \_\_\_\_\_