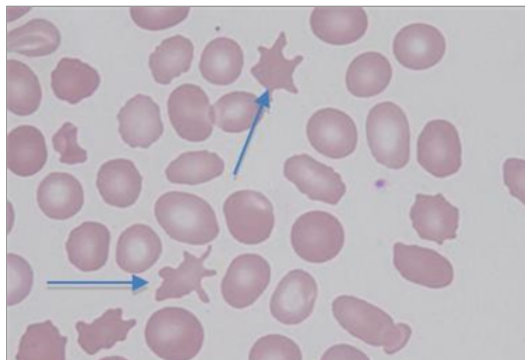


COMPETENCY TEST
RBC MORPHOLOGY

1 Identify arrowed cells

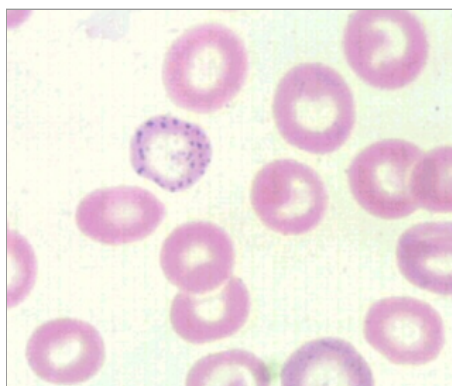
- Burr cell
- Acanthocytes**
- Macrocytes



EXPLANATION

2 Identify RBC morphology.

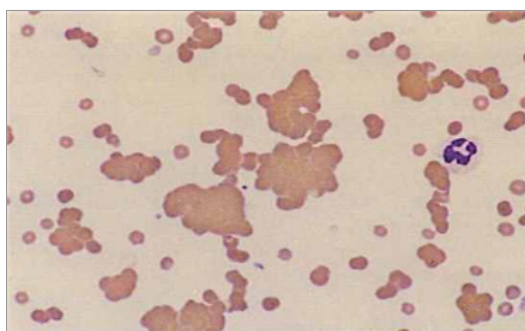
- Howell Jolly Bodies
- Basophilic stippling**
- NRBC



EXPLANATION

3 Identify RBC morphology

- Rouleaux
- RBC agglutination**
- hyperchromic

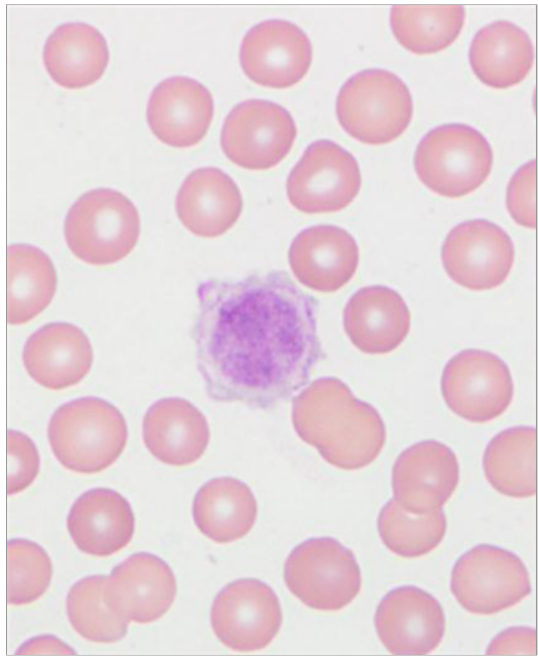


EXPLANATION

4 Identify large cell in middle of picture.

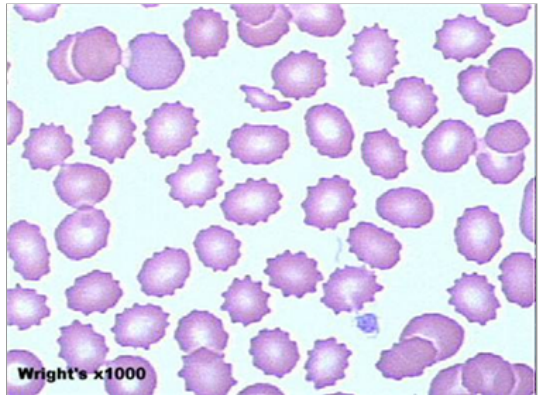
- Giant Platelet**
- Debris
- Normal Platelet

EXPLANATION



5 Identify RBC morphology

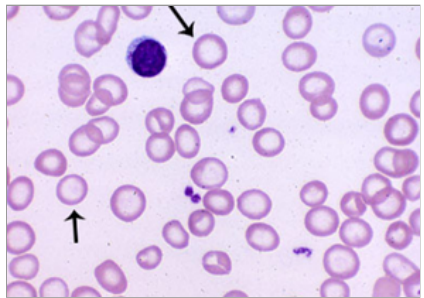
- Acanthocyte
- Burr Cell**
- microcyte



EXPLANATION

6 Identify arrowed cells

- Stomatocytes
- Hypochromic**
- Basophilic stippling



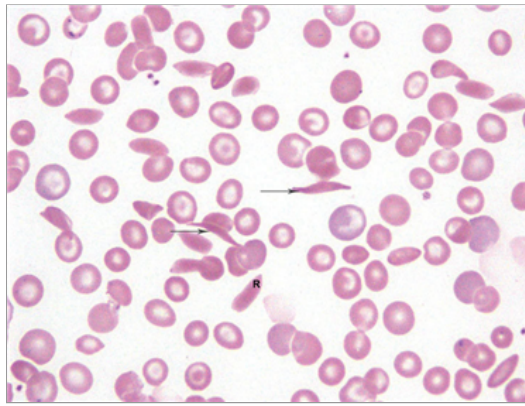
EXPLANATION

7 Identify arrowed cells

- Ovalocytes
- Sickle cells**
- Acanthocytes

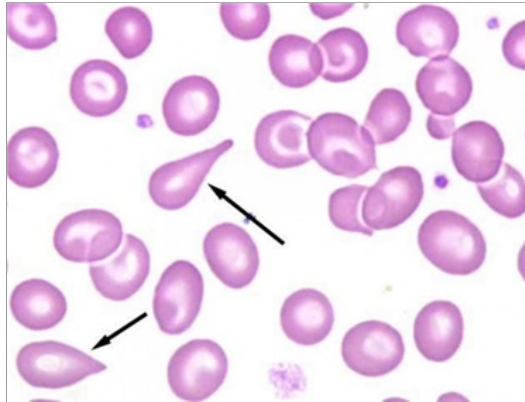
EXPLANATION

RBC MORPHOLOGY



8 Identify arrowed cells

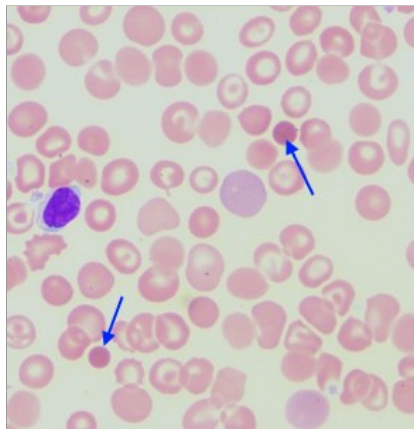
- Teardrops
- Ovalocytes
- Stomatocytes



EXPLANATION

9 Identify arrowed cells

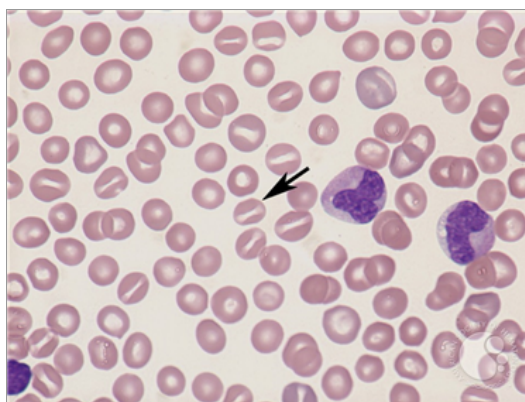
- microcytes
- macrocytes
- Spherocytes



EXPLANATION

10 Identify arrowed cells

- Ovalocytes
- Stomatocytes
- Sickle cells



EXPLANATION

