

Sample No.: 2616403
 Patient ID: 300955
 Name: MONA FRIEND
 Sample Comment:

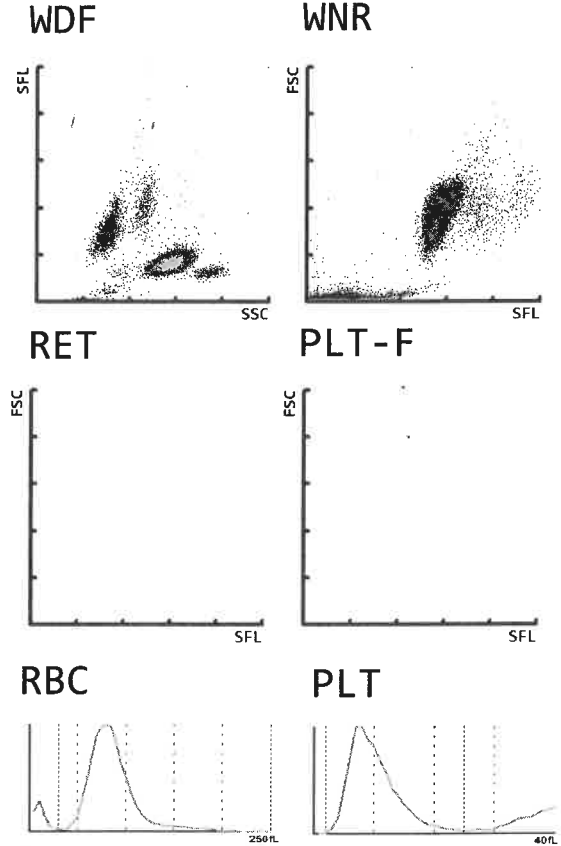
Rack: 64
 Ward:

Position: 10 11/16/2020 20:47:31 WB
 Doctor: SEAMAN
 Birth: 04/05/1972 Sex: Female
 Nickname: XN-2000-1-L

Positive Morph.

#55: Scan smear for abnormal RBC morph

WBC	8.89	[10 ³ /uL]		
RBC	4.81	[10 ⁶ /uL]		
HGB	12.1	[g/dL]		
HCT	39.4	[%]		
MCV	81.9 -	[fL]		
MCH	25.2 -	[pg]		
MCHC	30.7 -	[g/dL]		
RDW-SD		[fL]		
RDW-CV	20.1 +	[%]		
PLT	429 +	[10 ³ /uL]		
MPV		[fL]		
NEUT	67.9	[%]	6.03	[10 ³ /uL]
LYMPH	21.7	[%]	1.93	[10 ³ /uL]
MONO	5.7	[%]	0.51	[10 ³ /uL]
EO	3.6	[%]	0.32	[10 ³ /uL]
BASO	0.7	[%]	0.06	[10 ³ /uL]
IG	0.4	[%]	0.04	[10 ³ /uL]
NRBC	0.0	[%]		[10 ³ /uL]
RET		[%]		[10 ⁶ /uL]
IRF		[%]		
RET-He		[pg]		
IPF		[%]		
WBC-BF		[10 ³ /uL]		
RBC-BF		[10 ⁶ /uL]		
MN		[10 ³ /uL]		[%]
PMN		[10 ³ /uL]		[%]
TC-BF#		[10 ³ /uL]		



NEUT	
BAND	
LYMPH	
MONO	
EOS	
BASO	

META	
MYELO	
PRO	
BLAST	
ATYP	
NRBC	

MACRO	
MICRO	
HYPO	
POLY	
OVAL	
FRAG	

PLT	
OTHER	
TECH:	

WBC IP Message

RBC IP Message
 Anisocytosis

PLT IP Message